



# The prevalence of osteoarthritis of the sternoclavicular joint on computed tomography



Christopher R. Lawrence, BSc, FRCS(Tr&Ortho)\*, Benjamin East, BE(Hons), FRACS(Orth), Abbas Rashid, FRCS(Tr&Orth), Graham M. Tytherleigh-Strong, FRCS(Orth), DSportMed, FFSEM

*Shoulder Unit, Trauma & Orthopaedic Department, Addenbrookes Hospital, Cambridge University Hospitals NHS Trust, Cambridge, UK*

**Background:** Symptomatic disorders around the sternoclavicular joint (SCJ) are relatively uncommon. Previous cadaveric and radiographic studies have suggested that asymptomatic osteoarthritic changes are relatively common, progressively increasing with age. The purpose of this study was to determine the prevalence of SCJ osteoarthritis in the general population using computed tomography (CT) scans.

**Methods:** We assessed 464 SCJs in 232 patients undergoing a standardized axial CT scan of the thorax including both SCJs, across a range of ages from the second to tenth decade. The scans were undertaken for multiple clinical indications; however, none were obtained to investigate SCJ pathology. The predominant changes investigated were for the features associated with osteoarthritis including the presence of osteophytes, subchondral cysts, and subcortical sclerosis.

**Results:** The CT scans of 244 SCJs (53%) in 137 patients (59%) showed at least 1 sign of osteoarthritis. No patients younger than 35 years had any features of osteoarthritis. Osteoarthritic changes were present in 89.6% of patients older than 50 years compared with 9.1% younger than this age. All patients above the age of 61 had at least 1 feature of osteoarthritic changes on at least 1 side of the SCJ. Increasing prevalence was noted with increasing age both in the percentage of SCJs showing any positive signs of osteoarthritis and in the severity of osteoarthritis.

**Conclusion:** SCJ osteoarthritis is a very common incidental finding on CT scans, particularly with increasing age. This should be taken into consideration when using a CT scan to assess a patient with symptomatic SCJ pathology.

**Level of evidence:** Level III; Cross-Sectional Design; Epidemiology Study

© 2017 Journal of Shoulder and Elbow Surgery Board of Trustees. All rights reserved.

**Keywords:** Sternoclavicular joint; osteoarthritis; computed tomography; prevalence; age; cysts; osteophytes; sclerosis

Institutional Review Board approval was not required for this study in the United Kingdom.

\*Reprint requests: Christopher R. Lawrence, BSc, FRCS(Tr&Ortho), C/O L. Cilliers, Shoulder Unit, Trauma & Orthopaedic Department, Addenbrookes Hospital, Cambridge University Hospitals NHS Trust, Box 37, Hills Road, Cambridge, CB2 0QQ, UK.

E-mail address: [drclawrence@gmail.com](mailto:drclawrence@gmail.com) (C.R. Lawrence).

The sternoclavicular joint (SCJ) is the sole synovial articulation between the upper limb and the axial skeleton. Disorders around the joint in the form of degenerative and inflammatory arthritides, infection, and trauma do occur but tend to be treated nonoperatively because they are generally well tolerated.<sup>10</sup> However, in those situations in which the disorder is poorly

tolerated, the decision to manage nonoperatively is made in part because of concerns associated with the risks of surgery around the SCJ, as well as the previous diagnostic limitations associated with plain radiography. Advances in surgical techniques, particularly in the management of osteoarthritis (OA),<sup>13</sup> and greater access to computed tomography (CT) scans and other imaging modalities have led to increased interest in pathology around the SCJ.

Although often asymptomatic, the most common disorder affecting the SCJ is OA.<sup>4</sup> Previous studies looking at the prevalence of SCJ OA have been cadaver based at a microscopic level and radiographic using plain radiographs.<sup>7,11</sup> Both suggested that the onset of OA changes commenced in the third decade of life and that the majority of persons older than 60 years were affected. Although a common incidental finding, the prevalence of OA of the SCJ seen on routine CT scans has not previously been assessed.

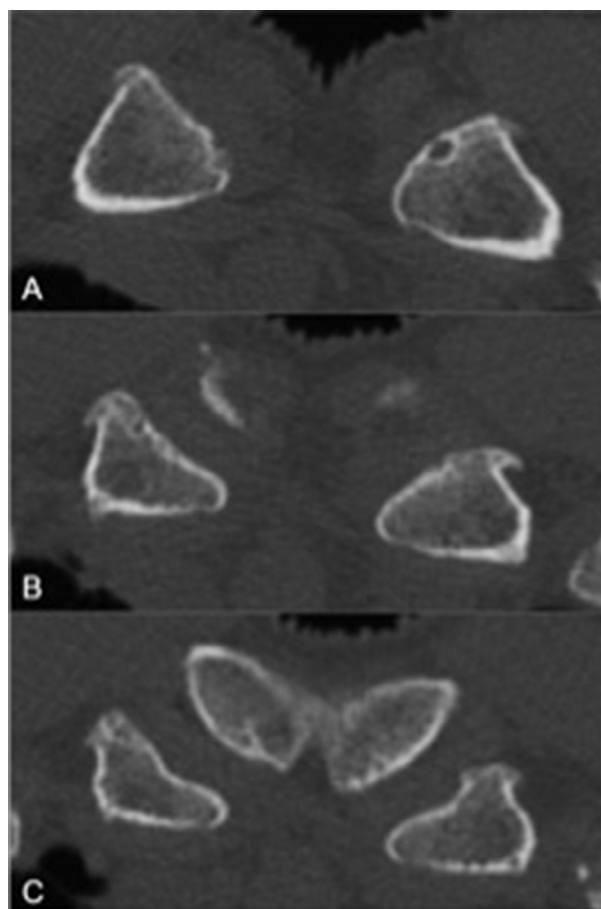
We assessed a large group of SCJ CT scans of patients ranging from the second to the tenth decade of life for changes associated with OA to determine the age-related prevalence. This allowed us to determine whether the degenerative findings on CT scans had a similar age-related distribution to the previous cadaver-based studies, as well as to assess the incidence of hypertrophic OA changes.

## Materials and methods

The online radiology database at our hospital was searched for CT imaging of the thorax. The routine axial sequences included the neck and whole chest, and therefore fine cuts of the SCJ were routinely available. The images were adjusted to the bone window and enlarged to twice standard zoom on a consistent viewing screen. Each CT scan had a maximum slice thickness of 2 mm, leading to a minimum number of 18 slices through each joint, extending from the most cranial part of the clavicular articular surface to the most caudal part of the sternal articular surface. The patients' position within the scanner and whether their arms were by their side or above their head were determined not to have an impact on the assessment because the reporting was based on the presence or absence of findings on the 2-mm slice and not based on the distribution of changes at the joint.

The CT scans were undertaken for a number of indications, including for diagnosis and staging of carcinoma, for investigation of various lung diseases, for investigation of infections, as part of a routine trauma series, and for various other reasons such as renal failure, upper gastrointestinal investigations, and autoimmune disease. None of the scans were undertaken to assess any SCJ or chest wall conditions. A range of ages was searched for and actively assessed to achieve a minimum of 20 patients or 40 SCJs in each 10-year age period from the second decade to the tenth decade. The selection of scans was based on type of scan and age only, with the analysis performed once the scan had been selected.

The changes assessed for were the presence of radiologic features that are associated with OA.<sup>6</sup> These were osteophyte formation, subchondral cysts, and cortical sclerosis. Because of the concavoconvex shape of the SCJ and the difficulty in obtaining symmetrical alignment of the joints, joint space narrowing has been shown to



**Figure 1** (A-C) Selection of images from a series of axial computed tomography slices from cranial (A) to caudal (C) displaying medial clavicle osteophytes, sternal sclerosis, and subchondral cysts.

be an inaccurate measure in CT assessment and so was not included.<sup>2</sup> Each scan was reviewed independently by 3 assessors (a post-FRCS orthopedic senior trainee [C.R.L.], a senior shoulder fellow [B.E.], and a consultant shoulder surgeon [G.M.T.-S.]) with the presence or absence of an OA change determined by a majority finding.

The sex of the patient was recorded, and the clavicular and sternal sides of each SCJ were assessed separately. A score of 1 point each was given for the presence of osteophytes, the presence of subchondral cysts, and the presence of sclerosis. The number of changes on the sternal and clavicular sides of each joint was recorded, along with the total for each side (a maximum score of 6 points), as well as the total for both joints for each patient, to give a relative indication of severity of OA. For the purposes of this study, we considered the presence of an osteophyte, a cyst, or sclerosis on either side of the joint (a score of  $\geq 1$  point) to be indicative of OA (Fig. 1).

If the axial anteroposterior width of the medial end of the clavicle on one side appeared to be more than 50% larger than that on the other side with evidence of OA changes and visible overlying soft-tissue protrusion on the CT scan, we considered it to be hypertrophic. This objective observation was used to apply a definition to the findings and allow the assessor to report the findings but has not previously been used. Any additional features

**Table I** Patient demographic data and results

	No. of SCJs (No. of patients)	% of SCJs showing presence of $\geq 1$ osteoarthritic change	Proximal clavicle findings, % of SCJs showing feature			Sternal articulation findings, % of SCJs showing feature		
			Osteophytes	Sclerosis	Cysts	Osteophytes	Sclerosis	Cysts
Age range, y								
<20	20 (5 F, 5 M)	0	0	0	0	0	0	0
20-29	54 (16 F, 11 M)	0	0	0	0	0	0	0
30-39	52 (7 F, 19 M)	15.4	13.5	5.8	3.8	1.9	0	1.9
40-49	50 (10 F, 15 M)	18	12.0	0	8.0	2.0	0	0
50-59	50 (16 F, 9 M)	58	38.0	30.0	36.0	12.0	8.0	8.0
60-69	86 (19 F, 24 M)	72.1	51.2	45.3	60.5	18.6	22.1	20.9
70-79	58 (11 F, 18 M)	84.5	67.2	53.4	70.7	17.2	25.9	20.7
80-89	50 (16 F, 9 M)	86	72.0	60.0	72.0	28.0	38.0	38.0
90-99	44 (7 F, 15 M)	100	77.3	86.4	84.1	63.6	79.5	70.5
Total	464 (107 F, 125 M)	52.6	39.9	33.6	40.9	16.4	19.8	18.3

F, female; M, male; SCJ, sternoclavicular joint.

such as the presence of physal opening in younger patients, chondrocalcinosis of the intra-articular disk, or gas in the joint were also recorded.

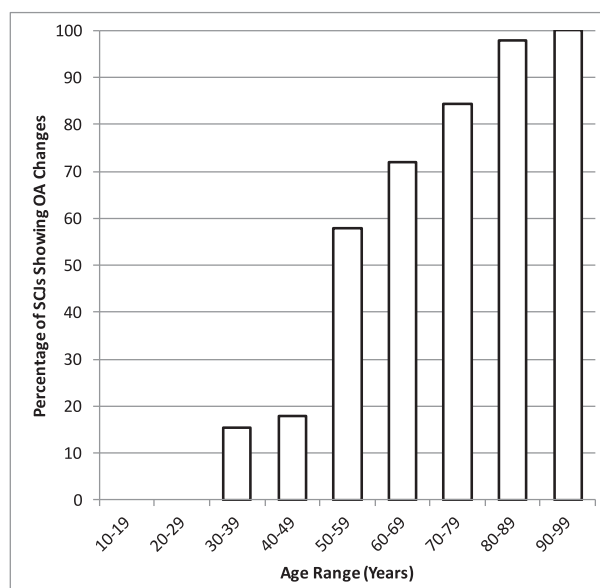
Statistical analysis was performed using the  $\chi^2$  test for categorical data and unpaired *t* test for continuous data, with  $P < .05$  considered statistically significant.

## Results

A total of 464 SCJs were assessed in 232 patients. The results are summarized in Table I. Overall, 244 SCJs (53%) in 137 patients (59%) showed at least 1 sign of OA. The changes were bilateral in 107 patients. Of the 244 OA joints, 240 had at least 1 sign of OA on the clavicular side compared with only 126 on the sternal side. In 118 cases, the changes were confined to the clavicular side alone, whereas the sternal side was exclusively involved in only 4 cases.

Increasing prevalence was noted with age both in the percentage of SCJs showing any positive signs of OA and in the severity of OA (Table I, Figs. 2 and 3). The mean age of patients showing no OA changes was 41.4 years compared with 73.1 years in those showing any feature of OA ( $P < .001$ ). No patients younger than 35 years had any features of OA on CT scans. All patients above the age of 61 had at least 1 feature of OA on at least 1 side of the joint. OA was present in 89.6% of patients older than 50 years compared with 9.1% of those younger than this age. At least 3 features of OA were present in 69% of SCJs in patients older than 70 years compared with 15% younger than that age. Moreover, 89% of patients older than 70 years had at least 1 joint with at least 3 features of OA.

There was no significant difference in the prevalence when we compared male patients with female patients ( $P > .05$ ), although there was a significant difference in the overall severity, with male patients displaying more changes than female



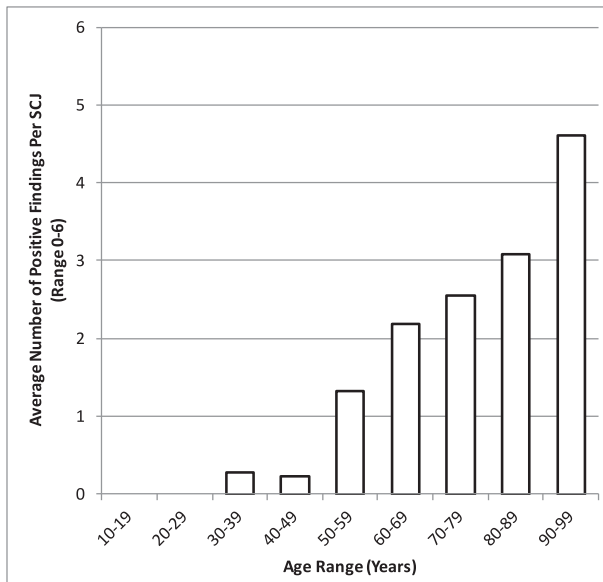
**Figure 2** Percentage of sternoclavicular joints (SCJs) showing any osteoarthritic (OA) changes in relation to age.

patients (with an average number of changes [out of 6] of 1.5 in female patients vs 1.9 in male patients,  $P = .024$ ).

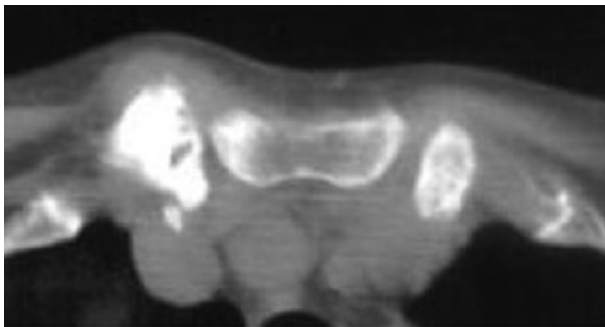There was no significant difference when we compared which side was affected ( $P > .05$ ), and there was a symmetrical distribution when we compared sides affected with age-related changes.

An open physis was noted in all SCJs in patients up to the age of 20 years and in some up to age 25 years. Gas was present in 33 joints, 20 of which showed signs of OA. The presence of gas was evenly distributed with age.

Hypertrophic medial clavicle changes were present in 3 patients, occurring bilaterally in 1 patient and on a single side in the other 2 patients (Fig. 4).



**Figure 3** Age-related increase in severity of osteoarthritic changes (average score per joint).



**Figure 4** Axial computed tomography scan from a 72-year-old male patient showing unilateral hypertrophic changes of the right medial end of the clavicle with sclerosis, cysts, and osteophyte formation, as well as prominence to the overlying soft tissues.

## Discussion

OA is the most common abnormality affecting the SCJ, and the risk factors include postmenopausal status, a history of radical neck dissection, and manual labor.<sup>4</sup>

Previous studies have looked at SCJ OA in relation to age. Silberberg et al<sup>11</sup> performed a cadaveric study on 200 patients across a range of ages. They undertook a histologic analysis of the articular cartilage and subchondral bone and were able to differentiate between age-related changes and OA changes. They found evidence of early age-related and OA changes from the third decade onward progressing to the presence of OA changes in over 90% of the patients from the seventh decade onward. Kier et al<sup>7</sup> looked at the radiographic changes of SCJ OA and correlated these with pathologic findings. They found OA to be rare in patients

under 40 years of age but moderate or severe in 53% of patients aged over 60 years. In our study we found the changes related to OA to broadly match these figures, with changes starting at age 35 years and gradually increasing in severity with increasing age. We found the SCJs to undergo physal closure at variable ages up to the middle of the third decade, with the vast majority of physes remaining open up to 25 years of age, and therefore, in keeping with the findings of Silberberg et al, did not become arthritic prior to this time.

Because of the presence of mediastinal and spinal structures, plain film radiographs do not achieve sufficient resolution at the SCJ to be used for the diagnosis of OA.<sup>1</sup> CT is an established technique for the diagnosis of SCJ OA and has been shown to be an excellent means of assessing the SCJ for OA changes.<sup>2,12</sup> The distribution and pattern of sclerosis, cystic changes, and osteophyte formation in the axial plane can be well demonstrated using CT scans; however, joint space narrowing is more difficult to assess.<sup>2</sup>

The severity of OA on radiographic imaging is often classified using standardized systems such as the Kellgren-Lawrence system.<sup>6</sup> These systems universally include joint space narrowing as part of the stratified system. Because of the concavo-convex shape of the SCJ and the difficulty in obtaining symmetrical alignment, any imaging, whether it be plain radiography, CT, or magnetic resonance imaging, is unable to reliably assess joint space narrowing. This meant that we were unable to apply a previously described standardized system for grading the severity of SCJ OA in this study. As a result, we used a more simplified system taking only sclerosis, cyst formation, and osteophyte formation on either side of the joint as the critical features associated with degenerative changes, with the sum of those changes indicating the severity. This system only took into account the presence of sclerosis, cysts, or osteophytes in a particular joint and not the extent, number, size, or distribution.

We could infer that the rate of CT OA changes in our study approximates to that in the population as a whole. Because this was an observational population study, the patients were not assessed for the presence or absence of symptoms, and the symptom of nontraumatic SCJ pain in general is an uncommon presentation.<sup>8</sup> The assumption is made that the vast majority of the patients studied were asymptomatic. The results of this study have shown the presence of SCJ OA on CT scans to be very common, with nearly 90% of patients older than 50 years showing changes. This finding leads to the conclusion that the presence of SCJ OA on CT scans is a common incidental finding, particularly with increasing age, and is unlikely to be clinically significant.

The results of this study suggest some useful clinical implications. OA is the most common nontraumatic source of pain and discomfort at the SCJ<sup>4</sup>; however, there are a number of other potential causes of pain, including disk pathology, infection, and inflammatory arthritides, that may not be shown on CT. If a CT scan is used as part of the diagnostic workup



for a patient with a symptomatic SCJ, it is important that the clinician be aware that OA changes are a very common incidental finding and, although possible, may not necessarily be the cause of the patient's symptoms.

Hypertrophic OA at the medial end of the clavicle can be the reason for patients to present with either a symptomatic or asymptomatic swelling at the medial end of the clavicle that they may perceive as appearing rapidly or gradually over time. Although standard OA changes were a common CT finding in our study, hypertrophic OA changes were rare (3 in 232 patients [1.3%]). It is also important that the clinician be aware of the relative rarity of hypertrophic OA at the SCJ and consider other possible causes such as infection, condensing osteitis, spontaneous dislocation, sternocostoclavicular hyperostosis, or malignancy (primary or secondary) as a potential differential diagnosis.<sup>3,5,9</sup>

There are a number of limitations to this study. As mentioned earlier, the actual population that we sampled comprised patients requiring a thoracic CT scan for a variety of clinical reasons; it cannot therefore be assumed to be wholly representative of the general population. We have quantified the severity of OA changes by the number of OA components (sclerosis, osteophytes, and subchondral cysts) present on either side of the joint rather than the extent of these. In grading the presence of OA as the presence of at least 1 of these changes, we have made a low threshold for the diagnosis. This will therefore give a high prevalence in the population as a whole rather than a picture of the spectrum of OA.

Interobserver error was kept to a minimum by having 3 assessors review all scans independently and achieve consensus agreement by majority on the findings. This method of analysis therefore has limitations in terms of interobserver variability. Viewing of the scans was standardized by using the same workstation to view the images at the same magnification under the same settings to minimize observational error.

We viewed thoracic CT images taken on consecutive days that had been stored in alphabetical order on the hospital picture archiving and communication system. This gave a cohort of patients that is likely to match population distributions, although it is not necessarily representative of the general population. It was also a selected group undergoing investigation and, therefore, not a random selection from a population. Because the majority of scans were performed for investigations and staging of various carcinomas (145 of 232 patients), the initial cohort matched the age distribution of patients with cancer, with a far greater number in the sixth to eighth decades and far fewer younger patients. As a result, it was necessary to actively select additional patients based on age to achieve an equal proportion of patients across all age ranges. There is therefore a bias toward acute trauma in the younger population in this study (mean age, 37 years) and male patients (12/14).

## Conclusion

The results of our study demonstrate that OA changes on standard CT scans are present at the SCJ from as early as 35 years of age and increase in prevalence and severity with increasing age. OA changes are likely to be a common finding in the general population, with nearly 90% of patients older than 50 years showing some evidence of these changes. The significance of SCJ OA changes seen on CT scans should be taken in clinical context, particularly in older patients, because it is likely that they may represent an incidental finding.

## Disclaimer

The authors, their immediate families, and any research foundations with which they are affiliated have not received any financial payments or other benefits from any commercial entity related to the subject of this article.

## References

1. Arlet J, Ficat P. Osteo-arthritis of the sternoclavicular joint. *Ann Rheum Dis* 1958;17:97-100.
2. Baker ME, Martinez S, Kier R, Wain S. High resolution computed tomography of the cadaveric sternoclavicular joint: findings in degenerative joint disease. *J Comput Tomogr* 1988;12:13-8.
3. Harden SP, Argent JD, Blaquiére RM. Painful sclerosis of the medial end of the clavicle. *Clin Radiol* 2004;59:992-9. <http://dx.doi.org/10.1016/j.crad.2004.04.019>
4. Higginbotham T, Kuhn JE. Atraumatic disorders of the sternoclavicular joint. *J Am Acad Orthop Surg* 2005;13:138-45. <http://dx.doi.org/10.5435/00124635-200503000-00007>
5. Hiramuro-Shoji F, Wirth MA, Rockwood CA Jr. Atraumatic conditions of the sternoclavicular joint. *J Shoulder Elbow Surg* 2003;12:79-88. <http://dx.doi.org/10.1067/mse.2003.128566>
6. Kellgren JH, Lawrence JS. Radiological assessment of osteo-arthritis. *Ann Rheum Dis* 1957;16:494-502.
7. Kier R, Wain SL, Apple J, Martinez S. Osteoarthritis of the sternoclavicular joint. Radiographic features and pathologic correlation. *Invest Radiol* 1986;21:227-33.
8. Noble JS. Degenerative sternoclavicular arthritis and hyperostosis. *Clin Sports Med* 2003;22:407-22. ix. [http://dx.doi.org/10.1016/S0278-5919\(02\)00097-2](http://dx.doi.org/10.1016/S0278-5919(02)00097-2)
9. Petrov D, Marchalik D, Lipsky A, Milgraum S. Asymptomatic enlargement of the clavicle: a review of underlying aetiologies. *Acta Orthop Belg* 2010;76:715-8.
10. Robinson CM, Jenkins PJ, Markham PE, Beggs I. Disorders of the sternoclavicular joint. *J Bone Joint Surg Br* 2008;90:685-96. <http://dx.doi.org/10.1302/0301-620X.90B6.20391>
11. Silberberg M, Frank EL, Jarrett SR, Silberberg R. Aging and osteoarthritis of the human sternoclavicular joint. *Am J Pathol* 1959;35:851-65.
12. Thongngarm T, McMurray RW. Osteoarthritis of the sternoclavicular joint. *J Clin Rheumatol* 2000;6:269-71.
13. Tytherleigh-Strong G, Griffith D. Arthroscopic excision of the sternoclavicular joint for the treatment of sternoclavicular osteoarthritis. *Arthroscopy* 2013;29:1487-91. <http://dx.doi.org/10.1016/j.arthro.2013.05.029>