

Functional Outcomes of Fixation Versus Replacement for Comminuted Radial Head Fractures in Adults: A Systematic Review

Akash Patel, Lily Li, Abbas Rashid

Akash Patel, FRCS, Orthopaedic registrar, Department of Trauma & Orthopaedics, St Mary's Hospital, London, W2 1NY, the United Kingdom

Lily Li, MRCS, Orthopaedic registrar, Department of Trauma & Orthopaedics, St Mary's Hospital, London, W2 1NY, the United Kingdom

Abbas Rashid, FRCS, Upper Limb Fellow, Upper Limb Unit, Wrightington Hospital, Wigan, the United Kingdom

Correspondence to: Lily Li, MRCS, Department of Trauma and Orthopaedics, Salton House, St Mary's Hospital, London, W2 1NY, the United Kingdom.

Email: XL228@doctors.org.uk

Telephone: +442033127974

Fax: +442033126034

Received: March 9, 2016

Revised: April 15, 2016

Accepted: April 17, 2016

Published online: June 23, 2016

ABSTRACT

AIM: The purpose of this systematic review was to search for and critically appraise articles directly comparing functional outcomes and complications for fixation (ORIF) versus arthroplasty for comminuted radial head fractures (Mason type 3) in adults.

MATERIAL AND METHODS: A comprehensive search of Medline, Embase and Cochrane databases using specific search terms and limits was conducted. Strict eligibility criteria were applied to stringently screen resultant articles. Three comparative studies were identified and reviewed.

RESULTS: Two studies found significantly better functional scores after replacement compared with ORIF in Mason type 3 fractures. The third study found no significant differences in functional score or range of motion, but did find that grip strength was better after ORIF. Complication rates were too heterogenous for conclusion.

CONCLUSION: Fixation with good reduction may be attempted in unstable Mason type 3 fractures, and arthroplasty may be

considered if this is not possible. Further randomised comparative trials are required to clarify the decision-making between fixation and replacement. Functional outcomes and complications were conflicting in the studies included here. Ideally, treatment decision should take into account elbow stability and degree of comminution.

Key words: Radial head fractures; Fixation; Arthroplasty; ORIF

© 2016 The Authors. Published by ACT Publishing Group Ltd.

Patel A, Li L, Rashid A. Functional Outcomes of Fixation Versus Replacement for Comminuted Radial Head Fractures in Adults: A Systematic Review. *International Journal of Orthopaedics* 2016; 3(3): 557-563 Available from: URL: <http://www.ghrnet.org/index.php/ijo/article/view/1635>

INTRODUCTION

Radial head and neck fractures account for 1.7% to 5.4% of all fractures seen^[1]. They are the most common fractures involving the elbow^[2,3] representing 33% of all elbow fractures^[4]. 85% of radial head fractures occur in patients aged between 20 and 60 years^[1]. Treatment is influenced by fracture characteristics such as fragment number, displacement, joint stability, and associated injuries^[5]. Options include early motion, fragment excision, radial head excision, fixation, or replacement^[2]. Studies of the optimal treatment of comminuted, unstable radial head fractures has been hindered by their relative infrequency and limited comparative data^[6].

Radial head fractures usually result from a fall onto the outstretched hand with the elbow extended and forearm pronated^[5]. Axial, valgus and postero-lateral rotational patterns of loading are responsible for these fractures^[3]. The radial head plays an important role in elbow stability. Several radial head fracture classification systems have been developed. The Mason classification^[7] is widely referenced to categorise radial head fractures^[6]. Mason type 1 is an undisplaced fracture; type 2 displaced marginal fractures; and type 3 comminuted fractures involving the entire radial head. Johnston^[8] also

added type 4, which categorises radial head fracture with an ulno-humeral dislocation. Broberg and Morrey^[9] further modified Mason's classification by including fractures of the radial neck and stratifying them based on articular segment displacement and fragment size. The Hotchkiss^[10] modification includes clinical examination and provides treatment guidelines for radial head fractures.

The goal of treatment of radial head fractures is preservation of elbow stability, motion and maintenance of radial length^[11]. There is a consensus that Mason type 1 fractures without mechanical block should be managed non-surgically with early active motion^[5,12]. Good results have been reported in 86-100% patients with type 1 fractures^[13]. Mason type 2, minimally displaced, isolated fractures with no block to motion may also be managed non-surgically with early active motion^[12]. Studies have shown 85-95% good results^[14]. Isolated Mason type 2 fractures with significant displacement or mechanical block should be reduced and internally fixed if possible^[15]. Options for fixation include Herbert screws, K-wires, plates, fibrin glue and bio-absorbable pins^[16]. Fragment excision may be considered if secure fixation cannot be achieved in patients with block to motion^[2].

Early studies advocated excision of Mason type 2 and 3 fractures^[16,17,18]. However, the biomechanical understanding of the radial head as a stabiliser and axial weight-bearing structure led to an appreciation of its functional importance. Excision has become less popular due to concerns about delayed sequelae and improvements in instrumentation for internal fixation and arthroplasty^[19]. Also, not all radial head fractures are amenable to simple excision because of concomitant injuries^[16]. Complications associated with excision include wrist pain, elbow stiffness, loss of strength, cubitus valgus, synostosis, instability, proximal radial migration, and degenerative arthritis^[20]. Broberg and Morrey^[21] reported that late excision is equally effective as early excision and may be used as a salvage procedure. Excision can also be considered in patients with isolated, displaced comminuted radial head fractures that are not amenable to fixation^[2]. Most comminuted radial head fractures, however, are not isolated^[22], and therefore excision alone is often contraindicated.

Choosing to re-establish radio-capitellar mechanics^[20] in Mason type 3 fractures by radial head arthroplasty or to preserve the radial head by internal fixation techniques remains controversial. Ring^[6] has discussed elbow stability and associated injuries which may be important in determining whether to fix or replace comminuted fractures. As advent of techniques and implants for internal fixation of comminuted radial head fractures developed, it became more popular to attempt to save complex fractures^[15]. Some authors have suggested fixation of all comminuted radial fractures, except those with greater than three fragments and where stable fixation may be difficult to achieve^[2]. However, combined with increased availability and use of radial head prostheses for comminuted fractures^[23,24], the role of fixation is being re-defined. A wide variety of radial head implants have been used since Speed published the first series of ferrule caps for the radial head in 1941^[25]. These include acrylic, cobalt-chromium, titanium and silicone^[26]. Many surgeons believe that it is important to preserve the native radial head, whereas others believe that reliable restoration of radio-capitellar contact with a prosthetic radial head may better address the goals of treatment for comminuted fractures^[27].

Numerous reviews evaluating fixation versus replacement for Mason type 3 radial head fractures have been published^[6,27]. However, none of these have been systematic in terms of search strategy. They all recommend the need for prospective randomised controlled and comparative studies. Therefore in this review, search

criteria specifically included comparative studies evaluating fixation versus replacement in adults with Mason type 3 radial head fractures.

METHODS

The Pubmed and Embase databases were searched on 18th June 2014 using keywords and strict eligibility criteria. The studies identified were further limited by selecting "English language articles" only. Duplicate studies were removed. The strategies for these searches are detailed in Tables 1 and 2. Only comparative studies evaluating fixation versus replacement for comminuted (Mason type 3) radial head fractures were included. The critical appraisal checklist (adapted from Critical Appraisal Skills Programme CASP, Oxford)^[28,29] and the revised CONSORT checklist^[30] for reporting randomised trials were used to guide assessment of the studies identified from the literature search. The full inclusion and exclusion criteria are detailed in Table 3.

Participants: Adults (over 18 years) with Mason type 3 radial head fractures.

Intervention: Surgical fixation with open reduction internal fixation.

Comparator: Radial head replacement.

Outcomes: Primary: functional outcome.

Secondary: complications.

RESULTS

A total of 92 studies were identified from the literature search (38 Medline, 47 Embase, 7 Cochrane). Of 23 relevant titles 10 were selected for full-text review after assessment of the abstracts. Three articles met inclusion criteria on full-text review (Figure 1). A summary of these three studies comparing fixation and replacement of Mason type 3 radial head fractures in adults is described in Table 4, and critique of the studies follows on Table 5.

DISCUSSION

The purpose of this systematic review was to determine whether fixation or replacement provides better functional outcomes for Mason type 3 radial head fractures. Chen *et al*^[31] concluded that metallic radial head replacement gave better joint function than ORIF. Ruan *et al*^[32] concluded that bipolar radial head replacement was better than ORIF. Boulas^[33] concluded that, when possible, ORIF provided better functional results than silastic replacement.

A number of methodological deficiencies were found in these studies. These included: small sample sizes; limited follow-up period; no controlling for confounding factors; no power calculation to determine probability of type II error; no observer blinding.

The small sample sizes in the studies may indicate selection bias, reporting bias, or both. The varying follow-up might indicate a significant amount of "missing" events and complications occurring after the follow-up period. Surgical methods were different in all three papers and no clear explanations were given for the types of fixation chosen. Fixation can be obtained with various implants, the goal being stable articular surface fixation and restoration of the head-neck relationship^[2]. Currently, fixation has become popular, since contemporary techniques have improved surgical outcomes^[15,36]. Good surgical outcomes have been shown in selected Mason type 3 radial head fractures and fracture dislocations stabilized with internal fixation^[37]. Complications of fixation include metalwork failure, irritation, non-union and poor forearm motion.

Table 1 Medline and Embase database search strategy.

Search terms	Medline	Embase
1 exp RADIUS FRACTURES/ AND exp ELBOW JOINT/	721	366
2 exp RADIUS/	7491	9941
3 (radius AND head).ti,ab	1572	1646
4 "radial head".ti,ab	1757	1884
5 head.ti,ab	223652	263240
6 2 AND 5	874	876
7 3 OR 4 OR 6	3040	3241
8 fracture*.ti,ab	173942	196596
9 7 AND 8	1326	1419
10 1 OR 9	1668	1648
11 exp FRACTURE FIXATION/	46682	63420
12 (fixation OR ORIF OR "open reduction internal fixation").ti,ab	102644	106378
13 11 OR 12	131425	142370
14 exp ARTHROPLASTY/	40292	48694
15 (arthroplasty OR replac*).ti,ab	334888	384221
16 14 OR 15	345928	397571
17 10 AND 13 AND 16	131	151
18 17 [Limit to: English Language]	105	124
19 exp FRACTURES, COMMUNUTED/ [Limit to: English Language]	1436	1934
20 (comminut* OR multifragment* OR splinter* OR crushed OR multi-fragment* OR unreconstructable).ti,ab [Limit to: English Language]	7409	8419
21 19 OR 20 [Limit to: English Language]	8084	9184
22 18 AND 21 [Limit to: English Language]	38	47

Table 2 Cochrane database search strategy.

1 radial head fracture*.ti,ab,kw (word variations have been searched)	30
2 Fixation:ti,ab,kw or ORIF:ti,ab,kw or open reduction internal fixation: ti,ab,kw (word variations have been searched)	4152
3 Arthroplasty:ti,ab,kw or replac*: ti,ab,kw (word variations have been searched)	19668
4 #1 and #2 and #3	7

Table 3 Summary of eligibility criteria.

Inclusion criteria	Exclusion criteria
Studies with emphasis on comminuted radial head fractures	Duplicate studies
Fixation/ORIF vs replacement/arthroplasty (comparative studies only)	Case reports, editorials, comments, letters, guidelines, protocols, abstracts, non-systematic review papers, demographic studies, unpublished studies
Patient outcomes data clearly discussed	Anatomical/cadaveric studies
Adults	Studies investigating only fixation or only replacement
English language articles	
Human studies	

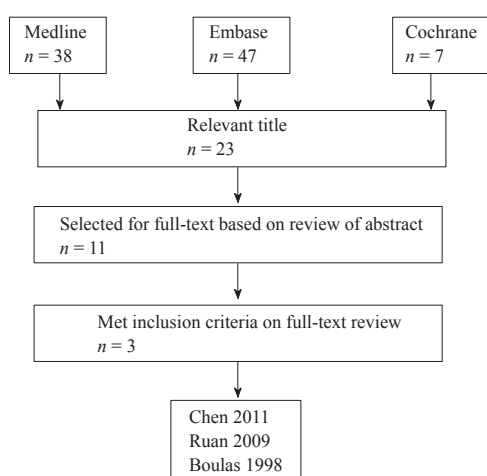


Figure 1 Flow diagram illustrating literature search and selection procedure.

Most radial head implants in use today are metal, consisting of cobalt-chrome or titanium. These have been found to restore axial and valgus stability, whereas silicone implants cannot^[26]. Comparative clinical evidence supporting a particular design concept for radial head arthroplasty, such as bipolar versus monopolar, cemented versus uncemented, and anatomic versus asymmetric head shape is not yet available^[2]. However, good to excellent results can be anticipated when radial head replacement is used for the correct indications and when care is taken to understand concomitant injuries^[25]. Recent clinical outcome studies of metallic radial head arthroplasty systems indicate it is a reasonable option to offer patients with comminuted radial head fractures^[19]. Specific complications include synostosis formation, heterotopic ossification, loosening and stiffness^[26].

The study by Boulas^[33] compared fixation to silastic replacement. Evidence has shown that silicone radial head implants have multiple complications^[38,39]. These include implant fractures and silicone synovitis. These complications and biomechanical studies showing

Patel A *et al.* Fixation versus replacement radial head fractures

the inability of silicone implants to support the radius functionally have lead to their disuse^[19]. However recently other authors have argued that the silastic implant can be used in a stable elbow with

good functional and radiographic results^[40]. Therefore Boulas' paper^[33] has been included in this systematic review. The inclusion of this study could be seen to be a limitation of this systematic review.

Table 4 Summary of studies.

Reference	Chen <i>et al</i> , 2011	Ruan <i>et al</i> , 2009	Boulas and Morrey, 1998
	(Comparison between radial head replacement and open reduction and internal fixation in clinical treatment of unstable, multi-fragmented radial head fractures)	(Comparative study of internal fixation and prosthesis replacement for radial head fractures of Mason type III)	(Evaluation of the elbow following radial head fracture. Comparison of ORIF vs. replacement, excision and non-operative management)
Study design ^a	Interventional comparative randomised study Level 4 evidence (Stated as "Prospective randomised controlled study level 1 evidence" by authors)	Interventional comparative randomised study Level 4 evidence	Interventional comparative non-randomised study Level 4 evidence
Research question ^b	+	+/-	-
Sample size ^c	Total 45 patients - 23 ORIF - 22 replacement	Total 22 patients - 8 ORIF - 14 replacement	Total 36 patients - 7 ORIF - 8 replacement - 13 excision - 8 non-operative
Participants	Mean age: - Combined ORIF/replacement 37 years Sex: - Combined ORIF/replacement 76% male/24% female All patients had Mason type 3 radial head fractures	Mean age: - ORIF 40.1 years - Replacement 37.4 years Sex: - ORIF 5 male/3 female - Replacement 8 male/6 female All patients had Mason type 3 radial head fractures	Mean age: - ORIF 37.3 years - Replacement 48.9 years Sex: - ORIF 3 male/4 female - Replacement 5 male/3 female Most patients had Mason type 3 radial head fractures
Intervention	Open reduction and internal fixation - AO mini fragment lag screws, plate, Kirshner wires	Open reduction and internal fixation - cannulated screws, Kirschner wires	Open reduction and internal fixation - AO mini fragment lag screws, buttress plate, Herbert screws
Comparator	Radial head replacement - Monopolar titanium prosthesis	Radial head replacement - Cement stem and bipolar prosthesis	Radial head replacement - Silastic prosthesis
Observer blinding ^e	+ (randomised block design)	-	-
Follow-up	Combined ORIF/replacement - 26 months (range 21 - 37 months) (not split into ORIF/replacement)	ORIF group - 14 months (range 10 - 21 months) Replacement group - 15.9 months (range 10 - 27 months)	ORIF group - 36 months (range 14 - 64 months) Replacement group - 49 months (range 12 - 96 months)
Removal of prostheses	ORIF (19) reason not stated Replacement -	ORIF (2) removed for metalwork irritation Replacement -	-
Primary outcomes	Broberg and Morrey functional elbow criteria: ORIF - excellent (9), good (6), fair (5), poor (3) Replacement - Excellent (15), good (5), fair (1), poor (1) Good/Excellent result in 65.2% ORIF group compared to 91% replacement group Statistically significant difference ($P < 0.01$; t -test and chi-squared test)	Broberg and Morrey functional elbow criteria: ORIF - good (1), fair (4), poor (3) Replacement - Excellent (9), good (4), fair (1) Good/Excellent result in 12.5% ORIF group compared to 92.9% replacement group Statistically significant difference ($P = 0.0004$; Fisher's exact test)	Mayo performance index (max score = 100): ORIF - mean 97.9 (range 85 - 100) Replacement - mean 94.4 (range 85 - 100) No significant difference in scores Motion at last follow-up: ORIF group mean - ext 10°, flex 146°, pron 70°, sup 66° Replacement group mean- ext 11°, flex 145°, pron 58°, sup 79° No significant difference in range of motion ($P < 0.05$) Strength (corrected for hand dominance): - Grip strength significantly higher in ORIF group ($P < 0.05$), no difference in other strength parameters
Secondary outcomes	Complications ^d : ORIF - non-union (1), range of motion deficit > 30° (4), fixation failure and fragment displacement (3), deep wound infection (1), heterotopic ossification (2) Replacement - range of motion deficit > 30° (2), joint stiffness (1) Statistically significant difference in complication rates ($P < 0.01$)	Complications ^d : ORIF group - non-union and k-wire loosening (4) Replacement group - heterotopic ossification (3)	Complications ^d : ORIF group - removal of metalwork due to irritation (2) Replacement group ^f - heterotopic ossification (4), prosthesis dislocation (1), breakage of prosthesis (1)

^aBased on modified Oxford Centre for Evidence-based medicine - Levels of Evidence (March 2009)³⁴; ^b(+) Well defined, in introduction; (+/-) well defined, after reading article; (-) not well defined; ^c(+) complete; (+/-) incomplete; (-) none; ^dnumbers in brackets indicate number of patients; ^e(+) described and performed; (+/-) described, not performed; (-) not described; ^fMorrey *et al* 35 (see references)

Table 5 Critical appraisal of studies.

Study	Clear statement of aims?	Is methodology appropriate?	Design appropriate to address aims?	Appropriate recruitment strategy?	Appropriate data collection?	Appropriate consideration of researcher/participant role?	Ethical issues considered?	Sufficiently rigorous data analysis?	Clear statement of findings?	How valuable is research?
Chen <i>et al</i>	Yes	Yes but study stated as "Prospective randomised controlled study level" by authors - on closer reading study better classified as level 4 comparative trial	Yes but design not clearly explained Patient-assessed, elbow-specific outcome score used	Clear inclusion/exclusion criteria No reference made to number of fracture fragments, stability and additional injuries Randomisation method for allocation of groups not stated No mention of allocation concealment Baseline demographics and clinical characteristics of pts not adequately discussed Non-matched groups	Prospective randomised controlled study Surgical technique of both methods stated but decision for choice of treatment methods within ORIF group not explained Clear post-operative rehabilitation regime stated No sample size calculation performed No outcome measures stated in methods section, only in results section Setting and location of data collection not stated Follow-up period clearly stated Radiographic parameters clearly defined	Grade of surgeon not stated Reviewers blinded by randomised block design All clinical assessments performed by independent observers	Approved by authors' institutional ethics committee	Appropriate statistical methods No power calculation No confidence intervals calculated	Statement of findings vague	Study linked to current knowledge/trends No mention of further work Relevant literature review conducted
Ruan <i>et al</i>	Yes	Yes	Yes but design not clearly explained Patient-assessed, elbow-specific outcome score used	Inclusion/exclusion criteria not clearly stated No reference made to number of fracture fragments, stability and additional injuries Randomisation method for allocation of groups not stated No mention of allocation concealment Baseline demographics of pts not adequately discussed Non-matched groups (2 old fractures in replacement group)	Comparative study Replacement technique stated clearly, ORIF technique stated very briefly Rehab regime stated but no details No sample size calculation performed No outcome measures stated in methods section, only in results section Setting and location of data collection not stated Follow-up period clearly stated	Number and grade of surgeon(s) not stated No mention of observer blinding	Not stated Conflicts of interest and sources of funding not stated	Appropriate statistical methods No power calculation No confidence intervals calculated	Statement of findings vague	Study linked to current knowledge/trends Brief suggestion of further work Relevant literature review conducted
Boulas and Morrey	Yes	Yes	Yes but design not clearly explained Clinician- and patient-assessed, elbow-specific outcome score used	Vague inclusion criteria, exclusion criteria not stated No reference made to number of fracture fragments, stability and additional injuries No mention of randomisation Baseline demographics and clinical characteristics of pts not adequately discussed Non-matched groups Fractures heterogeneous (not limited to Mason type 3), exact number of Mason type 3 not stated	Retrospective comparative study Surgical method or details of implants not adequately explained Decision for choice of treatment methods not explained No sample size calculation performed Setting and location of data collection not stated Rehab regime not stated Mean follow-up period stated Radiographic findings clearly defined	Number and grade of surgeon(s) not stated No mention of observer blinding Radiographic findings not independently verified	Not stated Conflicts of interest and sources of funding not stated	Appropriate statistical methods Factorial analysis of variance allowing multiple comparison used No power calculation No confidence intervals calculated	Clear statement of findings	Study linked to current knowledge/trends Basic review of literature conducted

Important factors in considering operative treatment for Mason type 3 radial head fractures include elbow stability, associated injuries and number of fragments. None of the studies identified in this systematic review gave this important baseline patient information. Recent studies have discussed the principles that guide decision-making in the management of comminuted radial head

fractures^[2,22,27]. Pike *et al*^[2] recommended ORIF when feasible for all displaced (> 2 mm) radial head fractures consisting of less than four fragments. They recommended radial head arthroplasty if ORIF was not feasible and in the presence of elbow instability or if greater than three fragments were present. Clembosky and Borretto^[27] attempted to repair all comminuted radial head fractures, as they concluded

radial head arthroplasty could not restore valgus stability when the medial collateral ligament was deficient. However, they stated that if stable fixation could not be achieved, there was a definite risk of early failure and non-union. They therefore recommended arthroplasty in these complicated comminuted fractures as it produced consistent results and was more straightforward than fixation. Considering these reviews, it is evident that the lack of detail regarding baseline characteristics of patients in the studies by Chen^[31], Ruan^[32] and Boulas^[33] is a major weakness. This is another limitation of this search strategy.

There are other factors that may have affected the findings of this systematic review. Firstly, only English language articles were included and this may have limited the breadth of literature review. Secondly, the search strategy was based on a computer search process. Computer searches may omit some articles, and consequently, limit the scope of the literature search^[41].

In conclusion, in our systematic review two studies found significantly better Broberg and Morrey functional scores after replacement compare with ORIF for Mason type 3 radial head fractures. The third study found no significant difference in functional score (Mayo performance index) or range of motion, but did find that grip strength was better after ORIF. Complication rates were too heterogenous for conclusion. Considering the small numbers of studies, limitations of the search strategy and methodological weaknesses within the studies included in this systematic review, it is not definitively possible to clarify whether fixation or replacement has better functional outcomes in patients with Mason type 3 radial head fractures. As discussed, the principles that guide decision making in the treatment of Mason type 3 radial head fractures include elbow stability and degree of comminution. Each individual case should take these factors into account and only then a decision on fixation or replacement should be made. To help clarify the decision making, randomised studies comparing the two treatment methods and taking stability into account are needed. This may be difficult as many unstable, comminuted fractures are difficult or impossible to fix^[6]. Future studies should also compare the various types of radial head implants in randomised comparative studies. Also, better data is required regarding the long-term outcome of metal radial head replacements.

COMPLIANCE WITH ETHICAL STANDARDS

The authors declare no conflict of interest in the writing of "Functional outcomes of fixation versus replacement for comminuted radial head fractures in adults: a systematic review".

No author has received internal or external funding or grants that assisted in this study.

Ethical statement

This article does not contain any studies with human participants or animals performed by any of the authors.

ACKNOWLEDGEMENT

The authors would like to thank Gill Jones for her help in compiling the literature search.

CONFLICT OF INTEREST

The authors declare that they have no conflicts of interest.

REFERENCES

- Morrey B. Radial head fracture. In: Morrey B, editor. *The elbow and its disorders*. 3rd ed. Philadelphia: WB Saunders, 2000: 341-364. ISBN 0721677525, 9780721677521.
- Pike J, Athwal G, Faber M, King G. Radial head fractures - an update. *J Hand Surg* 2009; **34A**: 557-565. doi: 10.1016/j.jhssa.2008.12.024.
- Rosenblatt Y, Athwal G, Faber K. Current recommendations for the treatment of radial head fractures. *Orthop Clin N Am* 2008; **39**: 173-185. doi: 10.1016/j.ocl.2007.12.008.
- Harrington I, Tountas A. Replacement of the radial head in the treatment of unstable elbow fractures. *Injury* 1981; **12**: 405-412.
- Harrison J, Chitre A, Lammin K, Warner J, Hodgson S. Radial head fractures in adults. *Current Orthopedics* 2007; **21**: 59-64. <http://dx.doi.org/10.1016/j.cuor.2006.10.003>
- Ring D. Displaced, unstable fractures of the radial head: Fixation vs replacement - What is the evidence? *Injury* 2008; **39**: 1329-1337. doi: 10.1016/j.injury.2008.04.011
- Mason M. Some observations on fracture of the head of the radius with review of one hundred cases. *Br J Surg* 1954; **42**: 123-132.
- Johnston G. A follow-up of one hundred cases of fracture of the head of the radius with a review of the literature. *Ulster Med J* 1962; **31**: 51-56.
- Broberg M, Morrey B. Results of treatment of fracture dislocations of the elbow. *Clin Orthop Rel Res* 1987: 109-119.
- Hotchkiss R. Displaced fractures of the radial head: internal fixation or excision? *J Am Acad Orthop Surg* 1997; **5**: 1-10.
- Schatzker J. Fractures of the radial head. In: Schatzker J, Tile M, eds. *The rationale of operative fracture care*. 2nd ed. Springer-Verlag, 1996: 131-135. ISBN 3540593888, 9783540593881.
- Roidis N, Papadakis S, Rigopoulos N, Basdekis G, Poulosides L, Karachalios T, Malizos K, Itamura J. Current concepts and controversies in the management of radial head fractures. *Orthopedics* 2006; **29**(10): 904-916.
- Sharpe F, Kuschner S. Radial head fractures. In: Baker C, Plancher K, editors. *Operative treatment of elbow injuries*. New York, NY: Springer-Verlag Inc, 2001: 207-233. ISBN 0387989056, 9780387989051
- Akesson T, Herbertsson P, Josefsson P-O, Hasserius R, Besjakov J, Karlsson M. Primary nonoperative treatment of moderately displaced two-part fractures of the radial head. *J Bone Joint Surg Am*, 2006; **88**(9): 1909-1914. doi: 10.2106/JBJS.E.01052.
- Ring D, Quintero J, Jupiter J. Open reduction and internal fixation of fractures of the radial head. *J Bone Joint Surg Am*. 2002; **84**: 1811-1815. No DOI
- Furry K, Clinkscales C. Comminuted fractures of the radial head: arthroplasty versus internal fixation. *Clin Orth Rel Res* 1998; **353**: 40-52.
- Hotchkiss R. Fractures and dislocations of the elbow. In: Rockwood C, Green D, editors. *Fractures in adults*. 4th ed. Philadelphia, PA: Lippincott-Raven, 1996: 929-1024. ISBN 039751509X, 9780397515097.
- McKee M, Jupiter J. Trauma to the adult elbow and fractures of the distal humerus. In: Browner B, Jupiter J, Levine A, Trafton P, editors. *Skeletal trauma*. 2nd ed. Philadelphia, PA: WB Saunders, 1998: 1455-1522. ISBN 0721668844, 9780721668840
- Calfee R, Madom I, Weiss R. Radial head arthroplasty. *J Hand Surg* 2006; **31A**: 314-321. doi: 10.1016/j.jhssa.2005.12.005.
- Morrey B, An K, Stormont T. Force transmission through the radial head. *J Bone Joint Surg* 1988; **70A**: 250-256.
- Broberg M, Morrey B. Results of delayed excision of the radial head after fracture. *J Bone Joint Surg Am*. 1986; **68**: 669-674.
- Riet R, Morrey B. Documentation of associated injuries occurring

- with radial head fracture. *Clin Orthop Relat Res* 2008; **466**: 130-134. doi: 10.1007/s11999-007-0064-8.
23. Knight D, Rymaszewski L, Amis A, Miller J. Primary replacement of the fractured radial head with a metal prosthesis. *J Bone Joint Surg* 1993; **75B**: 572-576.
 24. Moro J, Werier J, MacDermid J. Arthroplasty with a metal radial head for unreconstructable fractures of the radial head. *J Bone Joint Surg* 2001; **83A**: 1201-1211.
 25. Speed K. Ferrule caps for the head of the radius. *Surg Gynecol Obstet* 1941; **73**: 845.
 26. Stuffman E, Baratz M. Radial head implant arthroplasty. *J Hand Surgery* 2009; **34A**: 745-754. doi: 10.1016/j.jhsa.2009.01.027.
 27. Clembosky G, Boretto J. Open reduction and internal fixation versus prosthetic replacement for complex fractures of the radial head. *J Hand Surg* 2009; **34**(6): 1120-1123. doi: 10.1016/j.jhsa.2008.12.031.
 28. Guyatt G, Sackett D, Cook D. Users' guides to the medical literature. How to use an article about therapy or prevention. A. Are the results of the study valid? *JAMA* 1993; **270**: 2598-2601.
 29. Guyatt G, Sackett D, Cook D. Users' guides to the medical literature. How to use an article about therapy or prevention. B. What were the results and will they help me in caring for my patients? *JAMA* 1993; **271**: 59-63.
 30. Schulz K, Altman D, Moher D. CONSORT 2010 Statement: updated guidelines for reporting parallel group randomised trials. *BMJ* 2010; **340**: c869. doi: 10.1136/bmj.c869.
 31. Chen X, Wang S, Cao L, Yang G, Li M, Su J. Comparison between radial head replacement and open reduction and internal fixation in clinical treatment of unstable, multi-fragmented radial head fractures. *International Orthopaedics (SICOT)* 2011; **35**: 1071-1076. doi: 10.1007/s00264-010-1107-4.
 32. Ruan H, Fan C, Liu J, Zeng B. A comparative study of internal fixation and prosthesis replacement for radial head fractures of Mason type III. *International Orthopaedics* 2009; **33**: 249-253. doi: 10.1007/s00264-007-0453-3
 33. Boulas H, Morrey B. Evaluation of the elbow following radial head fracture. Comparison of open reduction and internal fixation vs. replacement, excision and non-operative management. *Ann Hand Surg* 1998; **17**(4): 314-320.
 34. No author named. Oxford Centre for Evidence-based Medicine - Levels of Evidence (March 2009). <http://www.cebm.net/oxford-centre-evidence-based-medicine-levels-evidence-march-2009/> (accessed 19 January 2015)
 35. Morrey B, Askew L, Chao E. Silastic prosthetic replacement for the radial head. *J Bone Joint Surg* 1981; **63A**: 454-458.
 36. McArthur R. Herbert screw fixation of fracture of the head of the radius. *Clin Orthop Relat Res* 1987; **224**: 79-87.
 37. Nalbantoglu U, Kocaoglu B, Gereli A, Aktas S, Guven O. Open reduction and internal fixation of Mason type III radial head fractures with and without an associated elbow dislocation. *J Hand Surg* 2007; **32A**: 1560-1568. doi: 10.1016/j.jhsa.2007.09.016
 38. Swanson A, Jaeger S, La Rochelle D. Comminuted fractures of the radial head. The role of silicone-implant replacement arthroplasty. *J Bone Joint Surg* 1981; **63A**: 1039-1049.
 39. Vanderwilde R, Morrey B, Melberg M, Vinh T. Inflammatory arthritis after failure of silicone rubber replacement of the radial head. *J Bone Joint Surg* 1994; **76B**: 78-81.
 40. Maghen Y, Leo AJ, Hsu JW, Hausmann MR. Is a silastic radial head still a reasonable option? *Clin Orthop Relat Res* 2011; **469**(4): 1061-1070. doi: 10.1007/s11999-010-1672-2.
 41. Colville-Stewart S. How to do a literature search. The essential researcher's handbook for healthcare professionals. 2nd ed. London: Bailliere Tindall, 2002: 35-53. ISBN 0702026360, 9780702026362.

Peer reviewer: Lior Koren, MD, Achziv 9/1, Yoqneam, Israel.