

## Giant paravertebral myxoma

A. Rashid · H. B. Abdul-Jabar · S. Karmani ·  
K. Rezajooi · A. T. H. Casey

Received: 7 March 2010 / Accepted: 9 May 2010 / Published online: 21 May 2010  
© Springer-Verlag 2010

**Abstract** The study design includes case report and clinical discussion. The objective was to describe a rare case of a giant intramuscular myxoma (IMM) presenting as a mass in the paravertebral muscles. Myxoma is a rare benign soft tissue tumour of mesenchymal origin. Although intramuscular presentation is common, they are rare in the paravertebral muscles and are characteristically <5 cm in length. We report the clinical and imaging features in a 70-year-old woman presenting with back pain, asymmetry of the waist and a mass in right paravertebral region. This was originally misdiagnosed as a juxtafacet synovial cyst after CT-guided biopsy. The mass was excised en bloc and sent for histology. This revealed a low-grade myxoid neoplasm with features of an IMM. The patient went on to make a complete recovery. To our knowledge, this is only the fifth case of paravertebral IMM reported in the literature and at approximately 15 cm in length may be the largest encountered in clinical practice.

**Keywords** Benign · Mesenchymal · Myxoma · Intramuscular · Magnetic resonance imaging

---

A. Rashid (✉) · S. Karmani  
Department of Trauma and Orthopaedics,  
Princess Royal Hospital, Lewes Road,  
Haywards Heath RH16 4EX, UK  
e-mail: abbasrashid.1978@gmail.com

H. B. Abdul-Jabar · K. Rezajooi · A. T. H. Casey  
Department of Spinal Surgery,  
Royal National Orthopaedic Hospital,  
Stanmore, UK

K. Rezajooi · A. T. H. Casey  
Department of Spinal Neurosurgery,  
National Hospital for Neurology and Neurosurgery,  
London, UK

### Case study

A 70-year-old woman presented to her osteopath with mild non-specific lower lumbar back pain. Her osteopath noticed some asymmetry of her waist and fullness in the right lumbar paravertebral region. He suggested that her general practitioner refer her to the orthopaedic department at her local hospital for a more formal assessment.

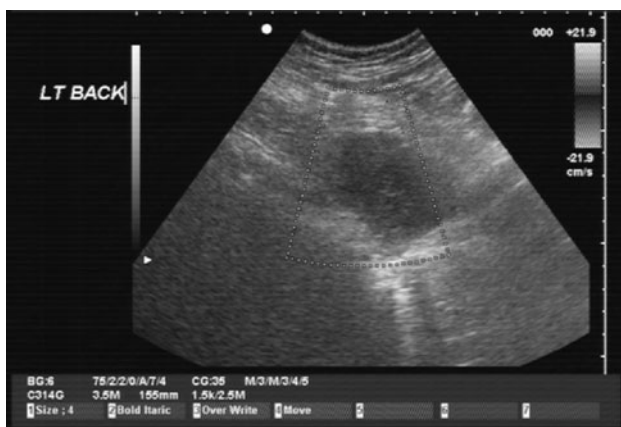
She reported a 6-month history of insidious onset dull aching pain in the lumbar region exacerbated by general physical activity. There were no constitutional symptoms, red flags or features of autonomic dysfunction. Her only relevant history was a craniotomy for excision of a left sphenoid wing meningioma several years previously. She did not smoke cigarettes and consumed alcohol occasionally. On examination, she had some asymmetry of the waist with fullness in the right lumbar paravertebral region. Her gait was normal and she had an unrestricted range of movement throughout the lumbar spine. The fullness was secondary to a paraspinal mass, which was non-tender and did not have a cough impulse. On neurological testing, she had unrestricted straight leg raise bilaterally without nerve root tension signs. The rest of the neurological examination was unremarkable.

Ultrasound scan showed a well-defined 6-cm area of hypoechogenicity in the right paravertebral musculature (Fig. 1), and an MRI was recommended for further characterization. This showed an unusual lesion lying within the right paravertebral muscles spanning L2 to S3. It appeared cystic with a lobular contour and multiple internal septations but the deep aspect of the lesion did have some lower signal on T2-weighted images. It was intimately related to several of the right sided lumbar facet joints with some evidence of bony destruction of the adjacent L4 transverse process (Fig. 2). Although some of these

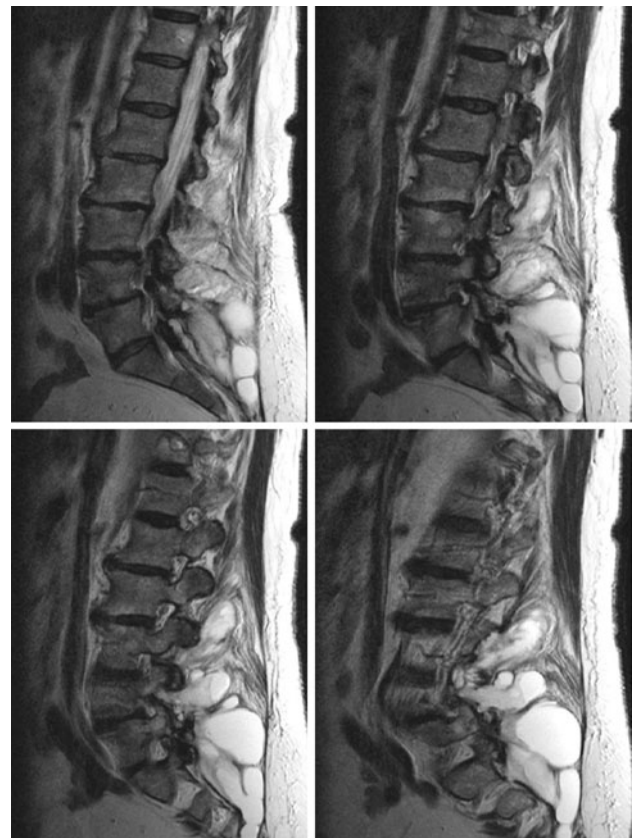
features were in keeping with an extensive ganglion cyst arising from the facet joint, the unusually large size and bony destruction meant that a neoplastic lesion could not be confidently excluded.

The patient was referred to the regional Bone and Soft Tissue Tumour unit for further investigation. It was decided she would undergo a CT-guided biopsy in the first instance. The lesion was accessed at the L4/5 facet joint level and 50 ml of straw-coloured gelatinous fluid was aspirated. 10 ml of iodinated contrast was instilled back into the lesion and the patient re-scanned after a 30-min delay. The contrast was seen to extend cranio-caudally highlighting multiple loculations (Fig. 3), implying that the lesion could represent a complex synovial cyst related to degenerate right L4/5 facet joint and extending cranio-caudally into the posterior paravertebral compartment. The histology showed a paravertebral synovial cyst with benign features.

As a diagnosis had been made the patient was referred to the Department of Spinal Neurosurgery at the National Hospital for Neurology and Neurosurgery to discuss treatment options. A complete excisional biopsy was recommended as the mass was just within the limits of a reasonably small operation with fairly limited risk. Furthermore, surgery would provide a definitive histological diagnosis. Pre-operative flexion/extension views of the lumbar spine did not show any undue instability which might have warranted intra-operative stabilization. At surgery, the mass was identified through a midline longitudinal incision and unilateral subperiosteal muscle strip. The mass was dissected free of the surrounding muscle and excised en bloc (Fig. 4). Histology showed a low-grade myxoid neoplasm of intramuscular origin. A year following her surgery, she is asymptomatic with no clinical or imaging evidence of recurrent tumour.



**Fig. 1** Pre-operative US. A well-defined 6-cm area of hypoechogenicity is seen in the right paravertebral musculature

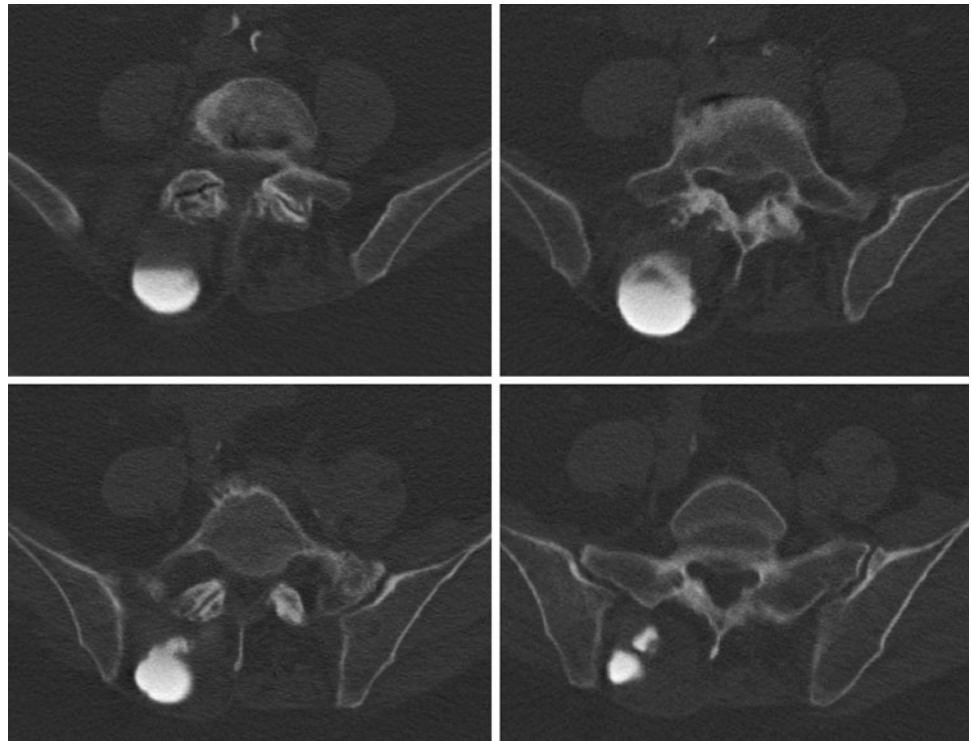


**Fig. 2** Pre-operative MRI. T2-weighted sagittal and parasagittal images show a loculated partially cystic mass lying within the right posterior paravertebral musculature. It is causing marked local expansion of the paravertebral musculature, has significant soft tissue component and some worrying bone erosion of the L4 transverse process indicating it may be aggressive in nature

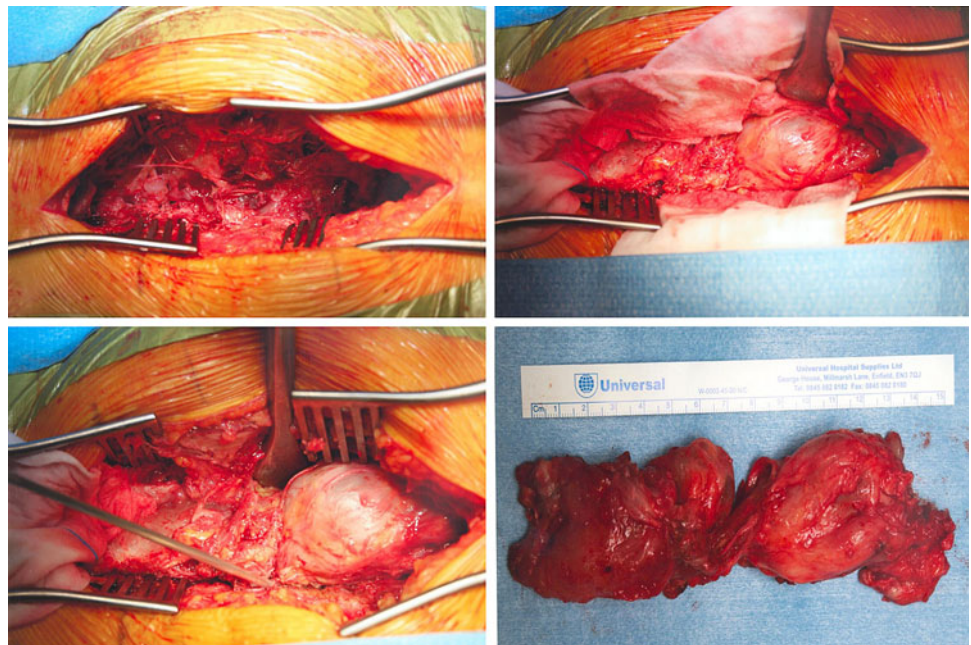
## Discussion

Myxomas originate from primitive mesenchymal stem cells that differentiate into altered fibroblasts and lose their ability to produce normal collagen, instead producing excess hyaluronic acid and immature collagen. They are uncommon benign lesions occurring in adults between the ages of 40 and 60 with a predilection for women [1]. The incidence varies between 0.1 and 0.13 per 100,000 of the population [2]. Approximately 17% of myxomas are intramuscular although they can occur in the skin, subcutaneous and aponeurotic tissue, the heart, bones, and the genitourinary tract [3]. Intramuscular myxomas (IMM) tend to occur in the muscles of the thighs, buttocks, upper limbs, and shoulders. They are not contained by a capsule and therefore infiltrate the adjacent muscle although they do not metastasize [4]. Presenting symptoms depend on the location and size of the lesion although they usually present as a solitary slow growing painless mass which is dormant for prolonged periods of time prior to sudden enlargement. They are characteristically <5 cm in length and

**Fig. 3** Pre-operative CT. An extensive soft tissue mass is seen arising from the right posterior elements at the L5 level. The cystic component extends down the posterior aspect of the sacrum. There is bone loss over the left side of the posterior elements of L4 involving the transverse process with expansion of the muscle bellies. The bony effects are seen involving both the posterior aspects of L4 and L5 making this unlikely to be a primary bony lesion, and more likely to be soft tissue in origin. The secondary bony change is in places marked making this lesion likely to have been present for some time



**Fig. 4** Intra-operative images. The mass was identified through a midline longitudinal incision and unilateral subperiosteal muscle strip. The mass was dissected free of the surrounding tissue and excised en bloc



consequently larger size usually implies an alternative diagnosis [5, 6]. To our knowledge, this is only the fifth case of paravertebral IMM reported in the literature and at approximately 15 cm in length may be the largest IMM encountered in clinical practice [7, 8].

Multiple soft tissue myxomas can occur on a background of fibrous dysplasia (usually the polystotic form). This is a rare condition known as Mazabraud's syndrome.

The soft tissue mass and the osseous lesions are located in the same anatomical region, although the fibrous dysplasia usually predates the IMM by several years. It has been suggested they result from basic metabolic errors of their tissues of origin during the initial growth period. While sarcomatous transformation is uncommon in fibrous dysplasia alone, the risk is much greater in Mazabraud's syndrome [9].

Plain radiography is usually normal or sometimes shows a non-specific soft tissue mass and further imaging is usually warranted. On US, IMM usually appears as a hypoechoic mass with small fluid-filled clefts, cystic spaces and absent intratumoural flow on colour Doppler. On CT, IMM usually appears as a well-circumscribed homogeneous low-density lesion within the skeletal muscle. There is no internal calcification or surrounding oedema and as a result the lesion will show mild enhancement or none at all. On MRI, IMM usually appears as low-signal intensity on T1-weighted images and high-signal intensity on T2-weighted, gradient echo (T2\*) or STIR images. Most lesions show mild enhancement after intravenous gadolinium injection. MR imaging planes along the long axis of the involved muscle yield the greatest information regarding tumour border definition and differentiation of signal in the lesion and the adjacent muscle. The lesion is surrounded by a ring of reactive fat, caused by muscle atrophy associated with the slowly growing mass [10].

IMM may be difficult to distinguish from intramuscular ganglion or neurofibroma, although these lesions usually arise from the intermuscular layer rather than being truly intramuscular in origin. Some malignant soft tissue tumours (liposarcomas, chondrosarcomas and malignant histiocytomas) can undergo myxomatous degeneration making them difficult to distinguish from IMM. In particular, the intramuscular myxoid liposarcoma has a predominantly myxoid morphology and has a similar gross and histological appearance to IMM making definitive diagnosis extremely difficult. Differentiating between these two lesions has significant implications for planning treatment as IMM has a benign clinical course, without tendency to recur or metastasize [9]. There are several key features which help to distinguish IMM from myxoid lesions. First, IMM has an infiltrative pattern of slow growth and will appear as having fluid-like signal intensity. Secondly, IMM does not have a capsule and will therefore infiltrate the adjacent striated muscle causing muscle atrophy which shows up as a peritumoural fat rind on T1-weighted MR images, and an increased signal in the adjacent muscle on T2-weighted or fluid-sensitive MR sequences. Finally, it is poorly vascularized, in contrast to myxoid liposarcoma which has a rich, delicate, plexiform capillary vascular network [11]. Soft tissue sarcomas, in contrast, have abundant mitotic activity, rich vascularity and specific cellular elements (lipoblasts or chondroblasts). On enhanced MRI, they will show signal heterogeneity on T<sub>2</sub>-weighted images, intense enhancement of 65–100% of the tumour volume and high signal intensity from fatty foci on T<sub>1</sub>-weighted MR images, septation, ill defined margins and invasion of adjacent structure. Therefore, although routine intravenous gadolinium is not warranted for every musculoskeletal mass, it is helpful in establishing the diagnosis of IMM.

Image-guided biopsy permits a preliminary diagnosis and surgical planning. The mainstay of treatment is simple myectomy or wide local excision which also provides a formal histological diagnosis. Recently, it has been reported that intramuscular low-grade myxoid neoplasm has histology common to both IMM and low-grade myxofibrosarcoma or myxoid malignant fibrous histiocytoma, characterized by the potential for local recurrence. In our case the histology showed a low-grade myxoid neoplasm of intramuscular origin. Local recurrence has been reported after sub-total excision. Therefore, the goal of surgery should be total tumour removal and any recurrence implies insufficient initial resection or incorrect diagnosis [12].

Macroscopically, the tumour is oval or spherical in shape, and when cut open it has a white or grey-white mucoid gelatinous surface. Small cyst-like spaces or traversing trabeculae may also be seen. It has an incomplete and delicate fibrous capsule allowing infiltration of adjacent musculature. Microscopically, myxoma is composed of undifferentiated stellate cells and an irregular meshwork of reticulum fibres in a matrix of hyaluronic acid-containing mucoid [13].

In conclusion, we report the clinical and imaging features of paravertebral IMM. This is a rare condition frequently confused with other soft tissue tumours. In our case, this was further complicated by its unusual location and uncharacteristically large size. Myxomas should be excised if pain or pressure symptoms develop. Excision also enables a formal histological diagnosis and more importantly the exclusion of malignancy especially in older patients.

**Acknowledgments** No funding was received for this work. The patient gave full consent.

**Conflict of interest statement** None of the authors has any potential conflict of interest.

## References

1. Caro P, Dubrana F, Le Nen D et al (1991) Myxome intramusculaire. *Rev Chir Orthop* 77:568–570
2. Heymans O, Gebhart M, Alexiou J et al (1998) Intramuscular myxoma. *Acta Chir Belg* 98:120–122
3. Enzinger FM (1965) Intramuscular myxoma, a review and follow-up study of 34 cases. *Am J Clin Pathol* 43:104–113
4. Bancroft LW, Kransdorf MJ, Menke DM, O'Connor MI, Foster WC (2002) Intramuscular myxoma: characteristic MR imaging features. *AM J Roentgenol* 178(5):1255–1259
5. Shugar JMA, Som PM, Meyers RJ et al (1987) Intramuscular head and neck myxoma: report of a case and review of the literature. *Laryngoscope* 97:105–107
6. Allen PW (2000) Myxoma is not a single entity: a review of the concept of myxoma. *Ann Diagn Pathol* 4(2):99–123
7. Guppy KH, Wagner F, Tawk R, Gallagher L (2001) Intramuscular myxoma causing lumbar radiculopathy. Case report and review of the literature. *J Neurosurg* 95(2 Suppl):260–263

8. Falavigna A, Righesso O, Volquind D, Teles AR (2009) Intramuscular myxoma of the cervical paraspinal muscle. *Eur Spine J* 18(Suppl 2):245–249
9. Kabukcuoglu F, Kabukcuoglu Y, Yilmaz B, Erdem Y, Evren I (2004) Mazabraud's syndrome: intramuscular myxoma associated with fibrous dysplasia. *Pathol Oncol Res* 10:121–123
10. Tan H, Peh WCG, Shek TWH (2001) A distinctive shoulder mass. *Br J Radiol* 74:1159–1160
11. Hashimoto H, Tsuneyoshi M, Daimaru Y, Enjoji M, Shinohara N (1986) Intramuscular myxoma: a clinicopathologic, immunohistochemical, and electron microscopic study. *Cancer* 58:740–747
12. Weiss SW, Goldblum JR (2001) *Enzinger and Weiss's soft tissue tumors*, 4th edn. Mosby, St. Louis, pp 1419–1481
13. Ozbek N, Danaci M, Okumus B, Gursel B, Cakir S, Dabak N, Karagoz F (2006) Recurrent intramuscular myxoma: review of the literature, diagnosis and treatment options. *Turk J Cancer* 36(2):75