

# Arthroscopic Sternoclavicular Joint Discectomy for Acute and Chronic Tears



Graham Tytherleigh-Strong, F.R.C.S.(Orth), Abbas Rashid, F.R.C.S.(Tr&Orth), Christopher Lawrence, F.R.C.S.(Tr&Orth), and David Morrissey, F.R.C.S.(Tr&Orth)

**Purpose:** To describe the results and functional scores in a group of patients who underwent arthroscopic excision of a symptomatic sternoclavicular joint (SCJ) disk tear with a minimum follow-up period of 2 years. **Methods:** Between April 2010 and December 2014, 14 patients underwent arthroscopic excision of a torn SCJ disk. Patients whose intended surgery was an isolated discectomy and underwent that surgery only, with no additional procedure, were included. The minimum follow-up period was 24 months. All patients underwent an arthroscopic SCJ discectomy. Postoperatively, no immobilization was required, and the patients were encouraged to mobilize as pain permitted. The patients were assessed preoperatively and at final follow-up with the visual analog scale score for pain, Rockwood score, and QuickDASH (short version of the Disabilities of the Arm, Shoulder and Hand questionnaire) score. **Results:** The average age at surgery was 29.4 years (range, 19-39 years). Ten of the patients had been symptom free before a specific incident, after which SCJ symptoms developed. The other 4 patients reported a gradual onset of symptoms and were considered to have chronic tears. The average duration of symptoms was 22.8 months (range, 6-48 months). At a mean follow-up of 33.4 months (range, 24-59 months), a significant improvement in the Rockwood score was noted, from 7 (range, 5-9; standard deviation [SD], 1.4) to 13.6 (range, 9-15; SD, 1.9) ( $P = .001$ ) (minimal clinically important difference not described). The mean QuickDASH score improved from 23.7 points (range, 6.8-40.9 points; SD, 11.8 points) to 8 points (range, 0-29.5 points; SD, 9 points) ( $P = .0024$ ) (minimal clinically important difference, 13.4 points). There were no reported complications and specifically no instability. **Conclusions:** The results of this series suggest that arthroscopic SCJ discectomy is a safe and reproducible procedure for the treatment of patients with symptomatic SCJ disk tears. **Level of Evidence:** Level IV, therapeutic case series.

The sternoclavicular joint (SCJ) is formed by the articulation of the medial clavicle with the clavicular notch of the sternum and the adjacent first costal cartilage. It is a saddle-shaped, diarthrodial joint and is the only true articulation between the axial and appendicular skeleton.<sup>1</sup> The articular surfaces are incongruent, and consequently, SCJ stability depends on the surrounding ligaments.<sup>2</sup> The joint contains a

fibrocartilaginous intra-articular disk that divides the joint into 2 compartments. The disk is attached superiorly to the articular margin of the medial clavicle and inferiorly to the first costal cartilage and the joint capsule. It acts as a checkrein against medial displacement of the clavicle.<sup>3</sup>

Like the meniscus in the knee, the SCJ intra-articular disk can undergo degenerative tears in the context of osteoarthritis and traumatic tears when the SCJ is dislocated or subluxated.<sup>4</sup> Although the proportion of tears that are truly symptomatic is presently unknown, there are studies that have shown the prevalence increases with age.<sup>5</sup> There are multiple reports in the literature of SCJ disk tears causing symptoms such as pain and clicking. Similar to the meniscus in the knee, it is anticipated that when conservative measures do not work, partial or complete disk excision may alleviate symptoms; however, descriptions in the literature are somewhat limited.<sup>6</sup>

Sternoclavicular arthroscopy has evolved over the past 10 years as a safe and effective technique to treat SCJ osteoarthritis and SCJ disk tears.<sup>4,7-10</sup> It has the

*From the Division of Orthopaedics, Addenbrooke's Hospital, Cambridge University Hospitals NHS Trust, Cambridge, England.*

*The authors report that they have no conflicts of interest in the authorship and publication of this article. Full ICMJE author disclosure forms are available for this article online, as [supplementary material](#).*

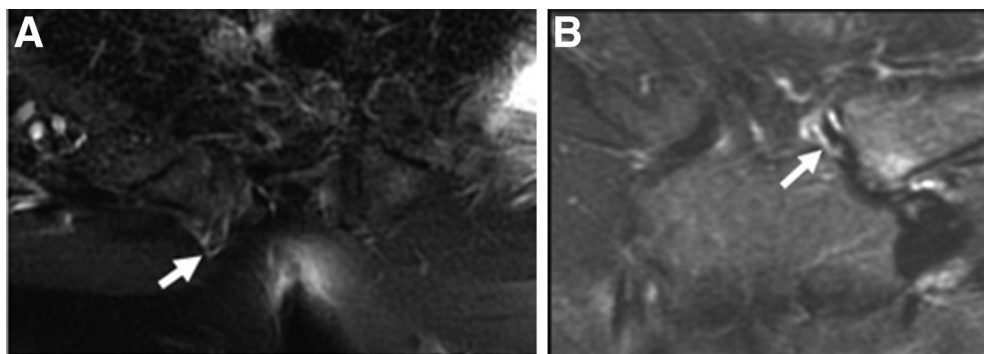
*Received January 5, 2017; accepted June 17, 2017.*

*Address correspondence to Graham Tytherleigh-Strong, F.R.C.S.(Orth), Division of Orthopaedics, Addenbrooke's Hospital, Cambridge University Hospitals NHS Trust, Cambridge, England. E-mail: [graham.tytherleigh-strong@addenbrookes.nhs.uk](mailto:graham.tytherleigh-strong@addenbrookes.nhs.uk)*

*Crown Copyright © 2017 Published by Elsevier on behalf of the Arthroscopy Association of North America. All rights reserved.*

*0749-8063/161247/\$36.00*

*<http://dx.doi.org/10.1016/j.arthro.2017.06.033>*



**Fig 1.** Fat-suppressed T2 magnetic resonance imaging. (A) Axial view showing signal consistent with a disk tear (arrow) with anterior extrusion. (B) Coronal view showing a torn disk (arrow) with characteristic wavy appearance.

advantage over an open procedure of not having to divide the anterior sternoclavicular ligament and so not requiring subsequent repair and immobilization, thus avoiding the potential risk of instability; moreover, it can be performed as an outpatient procedure.

The purpose of our study was to describe the results and functional scores in a group of patients who underwent arthroscopic excision of a symptomatic SCJ disk tear with a minimum follow-up period of 2 years. We hypothesized that there would be a significant clinical improvement regarding functional scores and pain after arthroscopic excision in patients with a symptomatic SCJ intra-articular disk tear.

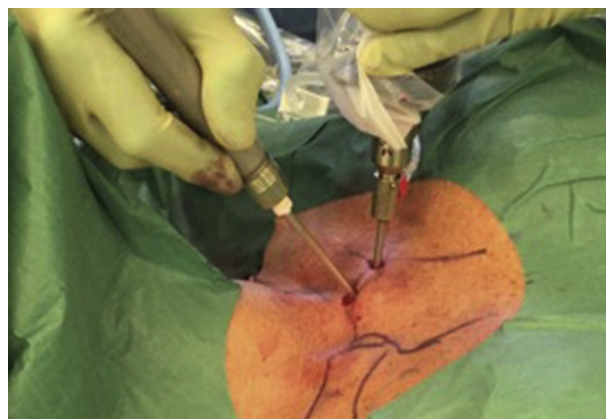
### Methods

The study was registered with our local audit office. We searched the database of the senior author (G.T-S.) for patients who underwent SCJ arthroscopy between April 2010 and December 2014. Patients whose intended surgery was an isolated discectomy and underwent that surgery only, with no additional procedure, were included. The exclusion criteria included patients with significant associated SCJ osteoarthritis, any previous SCJ surgery, or a history of SCJ infection.

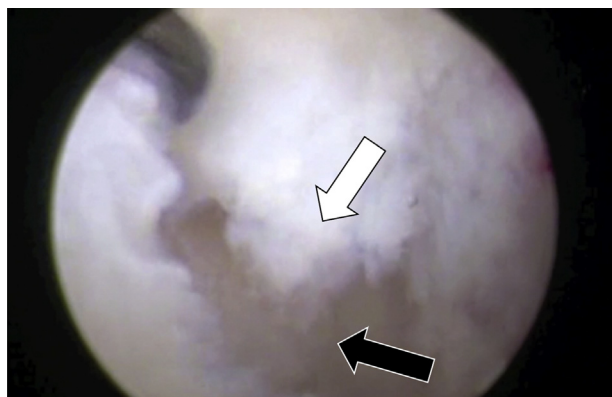
From the patients' medical records, we obtained details on the mechanism of injury, symptoms, examination findings, imaging (Fig 1), response to image-guided injection, and intraoperative findings. The primary outcomes were the visual analog scale (VAS) score for pain (0, no pain; 10, the worst pain); the score on the short version of the Disabilities of the Arm, Shoulder and Hand questionnaire (QuickDASH); and the Rockwood SCJ score. An increase of 8 or more points on the QuickDASH assessment has previously been identified as clinically significant.<sup>11</sup> The minimal clinically important difference (MCID) for the QuickDASH assessment has previously been described as a score change of more than 13.4 points.<sup>12</sup> The Rockwood score is an SCJ-specific patient-related outcome measure with 4 grades (from 0 to 3) available for pain, range of motion, strength, and functional limitation, as well as a subjective result (from 0 to 3). A total score of

13 to 15 is deemed excellent; 10 to 12, good; 7 to 9, fair; and less than 7, poor.<sup>13</sup> The MCID has not been described for the Rockwood score. The secondary outcomes were any recurrence of the preoperative symptoms and complications. All outcomes were compiled prospectively by a specialist nurse preoperatively and at final follow-up and were then reviewed retrospectively.

All of the procedures were undertaken by the senior author using the standard arthroscopic technique that has previously been described.<sup>14</sup> Under a general anesthetic, the patient was positioned supine with a small sandbag between the scapulae to help open the SCJ anteriorly for better arthroscopic access. The bony landmarks were marked, and an 18-gauge spinal needle was inserted at the inferior point below the anterior sternoclavicular ligament at an inclination of 30° to the vertical plane. The joint was distended with normal saline solution, an incision was made at the point of the spinal needle insertion, and a 2.7-mm arthroscope was inserted. A superior working portal was created above the anterior sternoclavicular ligament under direct vision with an outside-to-in technique (Fig 2). By use of a combination of a mini-punch, mini-shaver, and radiofrequency probe, the damaged disk was resected



**Fig 2.** Intraoperative external view showing the surface markings with the arthroscope in the inferior portal and the shaver in the superior portal.



**Fig 3.** Arthroscopic view of left sternoclavicular joint. The 30° arthroscope is on the clavicular side of the joint looking medially. There is an acute central disk tear (white arrow). The arthroscope is in the inferior portal, and the probe is in the superior portal. The sternal articular surface can be seen through the center of the tear (black arrow).

back circumferentially to its capsular origin (Figs 3 and 4). Hemostasis was achieved, the joint was lavaged, and the wounds were closed with sutures. Postoperatively, all patients were encouraged to mobilize as pain permitted.

Statistical analysis was performed with the Wilcoxon signed rank test to detect any differences in the preoperative primary outcome measures and at final follow-up.  $P < .05$  was considered statistically significant.

## Results

The inclusion criteria were met by 14 patients (6 women and 8 men), and the median follow-up period was 33.4 months (range, 24-59 months). The right side was involved in 8 patients. Ten patients reported a specific precipitating event (5 falls and 5 high-impact sporting collisions) before the onset of their symptoms (average age, 27.5 years [range, 19-35 years]). The other 4 patients reported a gradual onset of symptoms (average age, 34 years [range, 31-39 years]). All of the patients complained of “clicking” with varying levels of pain. The mean duration of symptoms was 26 months (range, 6-48 months). None of the patients had specific swelling, but all had tenderness on direct palpation over the anterior joint line of the SCJ. All had discomfort on protraction and/or retraction of the arm and crepitus on internal and external rotation of the SCJ, with 12 patients having a palpable click. The patients had previously undergone a variety of imaging modalities, but all had a magnetic resonance imaging (MRI) scan. In 12 patients a tear was identified on the MRI scan in either the axial or coronal view (Fig 1). Seven patients had undergone ultrasound-guided steroid or local anesthetic injections at their referring institution, all of whom had had some degree of transient benefit; in 3

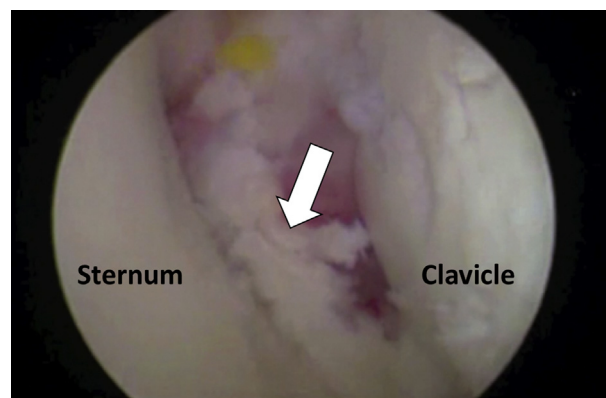
cases, this diminished with a second injection. All patients consented to undergo arthroscopic excision of the disk for pain relief. The mean age at surgery was 29.4 years (range, 19-39 years). None of the patients were excluded from the study or lost to follow-up, and the data of all 14 patients were included in the study.

At most recent follow-up, all patients reported a significant improvement regarding SCJ pain and crepitus. Eleven patients had complete resolution of the crepitus or clicking symptoms that they had had preoperatively, and 2 patients had minor residual symptoms. Ten patients had returned to their previous level of sporting activity. Preoperatively, the mean VAS score was 6.1 (range, 3-8); at most recent follow-up, this had improved to 1.2 (range, 0-4) ( $P = .001$ ). The mean Rockwood score had increased from 7 (range, 5-9; standard deviation [SD], 1.4) preoperatively to 13.6 (range, 9-15; SD, 1.9) ( $P = .001$ ) postoperatively. The clinical results were rated as excellent (score of 13-15) in 12 patients, good (score of 10-12) in 1, and fair (score of 7-9) in 1. Each of the individual factors contributing to the Rockwood score (pain, range of motion, strength, functional limitation, and subjective measure) showed an improvement in the score. The mean QuickDASH score improved from 23.7 points (range, 6.8-40.9 points; SD, 11.8 points) to 8 points (range, 0-29.5 points; SD, 9 points) ( $P = .0024$ ), an improvement of 15.7 points (MCID, 13.4) (Table 1).

There were no reported complications and specifically no problems with joint stability. Of the patients, 13 were pleased with the results and indicated they would be happy to opt for the procedure again.

## Discussion

The results of this study show that there was an improvement in SCJ function and pain after an arthroscopic SCJ diskectomy in patients with a symptomatic disk tear. At a median follow-up of



**Fig 4.** Arthroscopic view of the same left sternoclavicular joint shown in Figure 3 after resection of the torn disk back to a stable rim (arrow). The well-preserved articular surfaces on the sternal and clavicular sides of the joint are noted.

**Table 1.** Preoperative and Final Follow-Up Results

	Patients, n	Mean	Median	Minimum	Maximum	SD
Total	14					
Sex						
Male	8					
Female	6					
Side						
Left	8					
Right	6					
Age, yr		29.4	31	19	39	5.6
Length of symptoms, mo		22.8	23	6	48	11.3
Follow-up, mo		33.4	28	24	59	11.6
Rockwood score	14					
Preoperative (out of 15)		7	7	5	9	1.4
Postoperative (out of 15)		13.6	14	15	9	1.9
Improvement in score		6.6	6.5	4	10	1.8, $P = .001$
QuickDASH score	14					
Preoperative (out of 100)		23.7	21.6	6.8	40.9	11.8
Postoperative (out of 100)		8	4.5	0	29.5	9
Improvement in score		15.7	13.65	6.8	34.1	8.8, $P = .002$

QuickDASH, short version of Disabilities of the Arm, Shoulder and Hand questionnaire; SD, standard deviation.

33.4 months, in terms of the Rockwood score, Quick-DASH score, and VAS score, there had been statistically significant improvements.

The surgical anatomy of the SCJ and intra-articular disk has recently been described by Lee et al.<sup>15</sup> Contrary to most standard anatomic texts, their article noted that the superior part of the intra-articular disk not only blends into the superior capsule but also inserts into the upper third of the medial end of the clavicle. Although this central location makes direct injury to the disk less likely, its stable superior and circumferential attachment means that it is very vulnerable to damage after any significant shearing force (e.g., motor vehicle collision, sports-related injury, spontaneous dislocation in cases of generalized ligamentous laxity, or congenital deformity). This is supported by a study of 41 patients with SCJ pain after trauma, of whom 80% had disk injuries on MRI.<sup>16</sup> The SCJ can also undergo degenerative disk tears in patients with osteoarthritis, which is more prevalent with increasing age.

With advances in imaging techniques, the findings on clinical examination can be corroborated with both computed tomography and MRI, which are detailed enough to provide information on variations in disk anatomy such as central thinning and perforations. At our institution, we prefer MRI of the SCJ to specifically look at the disk. By imaging both joints simultaneously, it is possible to differentiate anatomic variations from tears, which are usually characterized by disk truncation and edema (Fig 4).

Previous reports of SCJ disk injury and its treatment are somewhat limited. This may, in part, be because of historical limitations in imaging capabilities, as well as concerns regarding the risk of an open procedure and

subsequent SCJ instability. As a result, in the literature, descriptions outlining operative treatment of SCJ disk tears are restricted to case reports. In 1931 Duggan<sup>17</sup> described a 37-year-old woman who noted a spontaneous swelling in the left SCJ while turning a heavy mattress. Surgery was indicated because of persistent pain and shoulder weakness. Intraoperatively, the disk could be seen herniating through a tear in the capsule. The disk was excised, and a capsular repair was performed. At 3 months' follow-up, the patient was pain free and had regained a full range of movement, albeit with intermittent weakness. In 1979 Pierce<sup>18</sup> described 4 patients who underwent open surgery for SCJ disk injuries. Three of these patients underwent disk excision and were noted to be asymptomatic and/or able to return to regular employment by the final follow-up (maximum of 8 months postoperatively). However, the patient who did not undergo disk excision had a protracted postoperative course. Delos et al.<sup>19</sup> in 2010 described 2 patients who had undergone a successful "meniscectomy" of the SCJ disk. The patients underwent an open arthrotomy and intraosseous repair of the anterior capsule. Postoperatively, they were immobilized in a sling for 6 weeks and then began to mobilize. A case report of 2 young active patients who underwent an arthroscopic disk excision was published in 2012.<sup>4</sup> One case was thought to be an acute-on-chronic disk tear, and the other, an acute tear. The patients were not immobilized, and at 6 weeks postoperatively, they were pain free with almost complete resolution of their symptoms. These results had been maintained at the 1-year follow-up.

Sternoclavicular arthroscopic surgery has previously been reported as a safe and reproducible procedure for intra-articular pathology.<sup>4,7-10,14</sup> Our indications for

SCJ arthroscopy include diagnostic, joint debridement, removal of loose fragments, excision of the disk, and resection of the medial end of the clavicle. In this reported series of arthroscopic disk excision cases, the anterior portals were positioned superior and inferior to the anterior sternoclavicular ligament and above the costoclavicular ligament. This allowed full access to the joint space without compromising joint stability. Clear visualization of the intact posterior capsule and observation that the instruments remained within the joint throughout the procedure ensured that the vascular structures posterior to the joint were not breached.

The earliest that a patient was seen in this series was 6 months after a specific injury. We chose to wait this long in a traumatic case to allow an adequate time for healing of any capsular damage that may have occurred, preventing posterior fluid extravasation during an arthroscopic procedure.

We suspect that the cause of the disk tears in the reported series was mixed. In the patients who reported an acute precipitating event, none were having any symptoms before their injury. In the younger patients from this group, it is likely that they had sustained an acute tear in a previously normal disk. With the knowledge that degenerative disk changes occur with increasing age, it is probable that the older patients may have sustained an acute-on-chronic tear in a previously degenerative disk.<sup>5</sup> In the group of patients who reported an insidious onset of symptoms, who were older, it is likely that they had sustained degenerative disk tears.

The patients in this study were drawn from a large population. Of the patients, 2 came from our own region, 10 came from within the United Kingdom and Ireland, and 2 came from Northern Europe. This is essentially the same study population that we have previously reported on regarding arthroscopic SCJ excision for the management of symptomatic SCJ osteoarthritis.<sup>9</sup> The only difference was that the average age of the patients in this study was 27.5 years compared with 53.2 years in the SCJ excision study. A computed tomography study looking at 464 SCJs in 232 patients showed osteoarthritic changes in 89.6% of the study group older than 50 years compared with 9.1% below that age and no evidence of osteoarthritis in anyone younger than 35 years.<sup>20</sup>

Because 12 of the 14 patients in our study were tertiary referrals, we do not know how many other patients had presented with symptomatic disk tears and achieved resolution with conservative measures or did not want to be considered for surgery. The 12 referred patients were essentially a select group who had all undergone workups before referral with MRI scans, whose symptoms had failed to improve after an adequate course of conservative treatment, and who were interested in the possible option of surgery. On

assessment by our team, they all met the inclusion criteria for surgery, and after receiving an explanation of the risks and benefits of surgery, they all wanted to proceed. Over the study period, there were no other referrals for consideration of an SCJ disk excision in patients who we believed were not appropriate for surgery or who did not want to proceed with an operation.

Although SCJ disk tears are relatively common, particularly in patients older than 50 years, their contribution to ongoing SCJ symptoms is presently unknown. However, there is limited evidence to suggest that disk tears can cause mechanical symptoms. In this series we found that arthroscopic excision of SCJ disk tears, refractory to conservative treatment, yielded satisfactory results. The clinical results were rated as excellent by 86% of the patients, and 79% had complete resolution of their preoperative symptoms. All but 1 of the patients were pleased with the results and indicated that they would be happy to opt for the procedure again.

### Limitations

This study is limited by the fact that it is a single-surgeon series, as well as the low number of patients and heterogeneity in presentation (type of tear, length of symptoms, and previous treatment). The follow-up time is also relatively short, and we do not know whether excising a symptomatic disk tear may accelerate, decelerate, or have no effect regarding the onset of subsequent degenerative arthritis. In addition, 12 of the 14 patients in this series had been referred from outside of our region. This might suggest that symptomatic disk tears are relatively rare; however, we suspect that this also may show that SCJ disk tears have been previously underdiagnosed.

### Conclusions

The results of this series suggest that arthroscopic SCJ diskectomy is a safe and reproducible procedure for the treatment of patients with symptomatic SCJ disk tears.

### References

1. Rockwood CA Jr, Wirth M. Disorders of the sternoclavicular joint. In: Rockwood CA Jr, Matsen F, eds. *The shoulder*. Philadelphia: WB Saunders, 1998;555-610.
2. Sewell MD, Al-Hadithy N, Le Leu A, Lambert SM. Instability of the sternoclavicular joint: Current concepts in classification, treatment and outcomes. *J Bone Joint Br* 2013;95:721-731.
3. DePalma AF. The role of the disks of the sternoclavicular and the acromioclavicular joints. *Clin Orthop* 1959;13:222-233.
4. Tytherleigh-Strong GM, Getgood AJ, Griffiths DE. Arthroscopic intra-articular disk excision of the sternoclavicular joint. *Am J Sports Med* 2012;40:1172-1175.

5. Silberberg M, Frank EL, Jarrett SR, Silberberg R. Aging and osteoarthritis of the human sternoclavicular joint. *Am J Pathol* 1959;35:851-865.
6. Brinker MR, Bartz RL, Reardon PR, Reardon MJ. A method for open reduction and internal fixation of the unstable posterior sternoclavicular dislocation. *J Orthop Trauma* 2007;11:378-381.
7. Tavakkolizadeh A, Hales PF, James GC. Arthroscopic excision of the sternoclavicular joint. *Knee Surg Sports Traumatol Arthrosc* 2009;17:405-408.
8. Tytherleigh-Strong G. Arthroscopy of the sternoclavicular joint. *Arthrosc Tech* 2013;2:e141-e145.
9. Tytherleigh-Strong G, Griffiths D. Arthroscopic excision of the sternoclavicular joint for the treatment of sternoclavicular osteoarthritis. *Arthroscopy* 2013;29:1487-1491.
10. Warth RJ, Lee JT, Campbell KJ, Millett PJ. Arthroscopic sternoclavicular joint resection arthroplasty: A technical note and illustrated case report. *Arthrosc Tech* 2014;3:e165-e173.
11. Mintken PE, Glynn P, Cleland JA. Psychometric properties in the shortened disabilities of the Arm, Shoulder and Hand Questionnaire (QuickDASH) and Numeric Pain Rating Scale in patients with shoulder pain. *J Shoulder Elbow Surg* 2009;39:920-926.
12. Van Kampen DA, Willems WJ, van Beers LW, Castelein RM, Schlotes VA. Determination and comparison of the smallest detectable change (SDC) and the minimal important change (MIC) of four shoulder patient-reported outcomes measures (PROMs). *J Orthop Surg Res* 2013;8:40.
13. Rockwood CA Jr, Groh GL, Wirth MA, Grassi FA. Resection arthroplasty of the sternoclavicular joint. *J Bone Joint Surg Am* 1997;79:387-393.
14. Tytherleigh-Strong G, Rashid A, Lawrence C, Morrissey D. Arthroscopic intra-articular disk excision of the sternoclavicular joint. *Arthrosc Tech* 2017;6:e599-e605.
15. Lee JT, Campbell KJ, Michalski MP, et al. Surgical anatomy of the sternoclavicular joint: A qualitative and quantitative anatomical study. *J Bone Joint Surg Am* 2014;96:e166.
16. Benitez CL, Mintz DN, Potter HG. MR imaging of the sternoclavicular joint following trauma. *Clin Imaging* 2004;28:59-63.
17. Duggan N. Recurrent dislocation of the sternoclavicular cartilage. *J Bone Joint Surg* 1931;13:365.
18. Pierce RO Jr. Internal derangement of the sternoclavicular joint. *Clin Orthop Relat Res* 1979;(141):247-250.
19. Delos D, Shindle MK, Mintz DN, Warren RF. Meniscectomy of the sternoclavicular joint: A report of two cases. *J Shoulder Elbow Surg* 2010;19:e9-e12.
20. Lawrence C, East B, Rashid A, Tytherleigh-Strong G. The prevalence of osteoarthritis of the sternoclavicular joint on computed tomography. *J Shoulder Elbow Surg* 2016;26:e18-e22.