



ELSEVIER

ORIGINAL ARTICLE

Linked semiconstrained and unlinked total elbow replacement in juvenile idiopathic arthritis: a case comparison series with mean 11.7-year follow-up

Edward F. Ibrahim, FRCS (Tr&Orth)*, Abbas Rashid, FRCS (Tr&Orth),
Michael Thomas, FRCS(Orth)

Wexham Park and Heatherwood Hospitals, Frimley Health NHS Trust, Slough, Berkshire, UK

Background: Few series report the results of total elbow replacement (TER) in patients with juvenile idiopathic arthritis (JIA). Most report the use of a linked implant. There are theoretical benefits to using an unlinked prosthesis, and thus we report our experience of the clinical benefit and survivorship of both this implant and a linked semiconstrained prosthesis.

Methods: There were 21 elbows replaced in 14 JIA patients (12 women and 2 men; 14 unlinked, 7 linked). Mean age at surgery was 39.5 years (range, 26-52 years). Mean clinical follow-up was 11.7 years (range, 5.4-17.6 years).

Results: Reoperation, including implant revision, was required in 9 elbows (42.9%). Using revision as an end point, survivorship was 95% (95% confidence interval [CI], 74%-99%) at 5 years and 68% (95% CI, 45%-86%) at 10 years. The 10-year survival was 70% (95% CI, 40%-89%) for the unlinked group and 69% (95% CI, 28%-94%) for the linked group. The need for bilateral TER was found to be a risk factor for revision within 10 years of primary surgery (6/11 vs. 0/7 elbows; $P = .037$). The rate of aseptic loosening seen on radiographs was high in the unlinked group (12/14, 85.7%), but many of these patients continue to function well without need for revision.

Conclusion: Both the unlinked Kudo 5 and linked Coonrad-Morrey prostheses for TER can provide benefits in the long-term for most patients with JIA. The need for bilateral TER in this group is associated with higher rate of revision at 10 years.

Level of evidence: Level III; Retrospective Cohort Design; Treatment Study

© 2016 Journal of Shoulder and Elbow Surgery Board of Trustees. All rights reserved.

Keywords: Total elbow replacement; elbow arthroplasty; juvenile arthritis; unlinked; linked; semiconstrained

Juvenile idiopathic arthritis (JIA) is defined as persistent arthritis of unknown etiology that begins before the age of

The subjects of this retrospective study of anonymized existing data were all UK NHS patients who had surgery in a single institution. NHS Research and Ethics Committee approval was deemed not necessary according to NHS Health Research Authority criteria.

*Reprint requests: Edward F. Ibrahim, FRCS (Tr&Orth), 4A Elms Road, Chalfont St Peter, Gerrards Cross, Buckinghamshire SL9 9QT, UK.

E-mail address: edward.ibrahim@uclmail.net (E.F. Ibrahim).

16 years, persists for at least 6 weeks, and cannot be explained by any other cause. It is the most common chronic rheumatologic disease in children, with an incidence of 1 per 10,000 every year.¹ The elbow is affected in 20% to 70% of patients, manifesting as pain, swelling, and stiffness eventually leading to severe joint destruction, soft tissue contractures, and abnormalities of growth.¹ Before advancements in disease-modifying medications, patients traditionally required multiple elbow operations throughout their

lifetime, with options including synovectomy with or without radial head excision, interposition arthroplasty, and total elbow replacement (TER).²⁰ Although functional outcomes of TER in inflammatory arthritis are thought to be as good as in non-inflammatory arthritis, the juvenile group is thought to do comparatively worse because of the usual early requirement for replacement and aggressive nature of the disease.^{8,12} Furthermore, arthroplasty can be technically difficult in these patients as they often have small and variably shaped osseous anatomy as well as significant soft tissue contracture.⁶ Such changes are due to the effect of an active inflammatory arthritic process on the growing skeleton that makes the juvenile idiopathic disease different from adult inflammatory arthritis when a normal skeleton has developed before the onset of the disease.¹⁵

To our knowledge, there are only 2 published series reporting the results of TER in patients with JIA exclusively, and both originate from the Mayo Clinic (Rochester, MN, USA).^{4,5} Baghdadi et al recently reported long-term follow-up of 24 patients (29 elbows) using a linked semiconstrained prosthesis.⁴ Sixteen years earlier, Connor and Morrey first reported the outcome of TER in 19 patients (24 elbows) with JIA. Whereas the majority of patients in this series received a linked semiconstrained design, an unlinked resurfacing-type implant was used in 6 elbows.⁵ Dennis et al also reported the results of 6 unlinked TERs in a subset of patients with JIA as a part of a larger series of patients with rheumatoid arthritis.⁷ We believe that these 2 studies remain the only published experience of using unlinked TER in JIA to date.

The purpose of this study was to report our experience of TER in this complex group of patients, with emphasis on the results of an unlinked design.

Materials and methods

We identified consecutive patients with JIA who underwent TER at our institution from 1997 to 2007 through our arthroplasty database. The decision to proceed to TER was based on pain, limited movement, or elbow instability prohibiting normal daily function, combined with Larsen grade 4 or 5 changes on plain radiography.¹¹ Where there was sufficient bone and soft tissue support, the unlinked Kudo 5 prosthesis (Biomet UK Ltd, Swindon, UK) was used (unlinked group). In elbows with significant bone loss, potential soft tissue compromise, and instability, the semiconstrained Coonrad-Morrey prosthesis (Zimmer, Warsaw, IN, USA) was used (linked group). All preoperative radiographs were then templated, and if necessary, smaller customized implants were requested from the manufacturer to account for small skeletal stature. All procedures were performed by the senior author.

Operative technique

The patient was placed in the lateral decubitus position. A posterior midline skin incision was made and Newcastle approach performed.³ The radial head (if present) was resected, and the ulnar nerve was decompressed within the cubital tunnel and within the

2 heads of flexor carpi ulnaris up to the level of the first motor branch and protected throughout the procedure but not transposed. Soft tissue releases were performed to gain adequate access, including release of the medial collateral ligament in its entirety irrespective of which type of implant was being inserted. The intramedullary canal of the humerus and ulna was identified, opened using a burr, and expanded with a malleable plastic sucker to prevent breach of the potentially thin and fragile cortical bone. Once the intramedullary canal was satisfactorily exposed, it was enlarged carefully with a burr together with solid and flexible metal reamers. Trial components were inserted, checking specifically for range of movement, tracking, and stability. Bone plugs were used as cement restrictors, and antibiotic-loaded cement was routinely inserted using a cement gun with a delivery system that accommodated the small intramedullary canals present in this group of patients. Postoperatively, a nocturnal thermoplastic extension splint was used for 4 weeks, with patients encouraged to perform active flexion during the day.

Data collection

Retrospective review of data routinely collected in our arthroplasty database was undertaken. Pain score, range of movement, function, stability, complications, and Mayo Elbow Performance Score (MEPS)¹⁴ were recorded preoperatively and then on a yearly basis postoperatively until latest follow-up or time of revision. A MEPS below 60 represents poor function, 60 to 74 is fair, 75 to 89 is good, and above 90 is excellent. In the instances in which a patient has moved away from our area, telephone consultation is routinely employed at our institution. When they were available, radiographs from the most recent clinic visit were assessed for signs of loosening, instability, fracture, and bushing wear (linked implants only).

Statistical analysis

Survivorship analysis was carried out by the Kaplan-Meier method, and survival probability estimates were compared between unlinked and linked groups using a nonstratified log-rank test. Preoperative and postoperative MEPS were compared using Student *t*-test. Comparison revision rates for patients with bilateral and unilateral disease as well as for those who did and did not have prior surgery were analyzed using Fisher exact test. A result was considered statistically significant when $P < .05$.

Results

There were 21 TERs performed in 14 patients (12 men, 2 women; [Table I](#) and [Supplementary Table I](#)). The dominant elbow was replaced in 10 of 21 cases. The mean age at diagnosis of JIA was 7 years (range, 4-13 years), whereas the mean age at TER was 39.5 years (range, 26-52 years). Nine patients (14 elbows) were included in the unlinked group and 5 patients (7 elbows) in the linked group, meaning that the proportion of patients who had bilateral TER was greater in the unlinked group (5/9 vs. 2/5). Of 21 elbows, 9 had undergone previous surgery (7 fascia lata interposition arthroplasty and 2 radial head excision plus synovectomy),

Table I Summary of clinical data comparing the whole cohort and unlinked and linked groups

Patients	Number	Overall	Unlinked	Linked
		14	9	5
Elbows	Number	21	14	7
	Mean age at surgery, years (range)	39.5 (26-52)	37.6 (26-52)	43.7 (34-50)
	Previous surgery	9	6 (2 RHE, 4 IA)	3 IA
Implants	Fully cemented	13 (61.9%)	5 (35.7%)	7 (100%)
	Customized	6 (28.6%)	4 (28.6%)	2 (28.6%)
Follow-up	Including revisions, years (range)	10.3 (2.1-17.6)	10.7 (2.1-17.6)	9.4 (5.3-16.6)
	Excluding revisions, years (range)	11.7 (5.4-17.6)	12.3 (7.7-17.6)	10.9 (5.4-16.6)
MEPS	Preoperatively	26.7 (5-50)	24.3 (5-45)	31.4 (20-50)
	2 years postoperatively	85.0 (65-100)	85.4 (65-95)	84.3 (80-100)
	Last follow-up (surviving implants only)	87.1 (70-100)	86.4 (70-100)	88 (80-100)
Complications	All	13 (61.9%)	8 (57.1%)	5 (71.4%)
	Requiring any secondary procedure	9 (42.9%)	7 (50.0%)	2 (29.6%)
	Requiring implant exchange	8 (38.1%)	6 (42.9%)	2 (28.6%)

IA, interposition arthroplasty; RHE, radial head excision and synovectomy; MEPS, Mayo Elbow Performance Score.

and these were proportionately distributed between linked and unlinked groups (6/14 vs. 3/7).

Follow-up

The follow-up period was defined as the time elapsed from date of primary TER to date of the last follow-up or date of revision surgery for those cases that required it. One patient (2 linked TERs) died (of unrelated causes), but no other patient was lost to clinical follow-up. For surviving implants, the mean postoperative clinical follow-up was 11.7 years (range, 5.4-17.6 years). Postoperative radiographic follow-up was shorter (mean, 9.3 years; range, 2.3-16.6 years) as 3 patients (3 elbows) moved away from the area and were not able to return for radiographs. Including revision as an end point, mean postoperative clinical follow-up for the entire cohort was 10.3 years (range, 2.1-17.6 years), 10.7 years (range, 2.1-17.6 years) for the unlinked group and 9.4 years (range, 5.3-16.6 years) for the linked group.

Implants

There were 14 unlinked Kudo and 7 linked semiconstrained Coonrad-Morrey prostheses implanted. Of the 14 Kudo prostheses implanted, 10 were small off-the-shelf implants, 2 were customized preoperatively by the manufacturer, and 2 had their ulna components customized intraoperatively by the surgeon (the straight stem of the ulna component was shortened to prevent engagement of it on the cortex of the proximal ulna). Nine Kudo TERs were implanted using uncemented humeral components; the other 5 had cemented humeral stems. All 14 Kudo ulnar prostheses were cemented. Of the 7 Coonrad-Morrey prostheses used, 5 were small off-the-shelf implants and 2 were customized preoperatively by the manufacturer to make them smaller. The extra-small extra-

long prosthesis was unavailable at the time of surgery, but these were introduced as standard components to the UK after.

Revisions

Of 21 TERs, 8 (38.1%; 6/14 unlinked and 2/7 linked implants) were revised with exchange implants during the study period. According to the Kaplan-Meier method as applied to the cohort as a whole, with revision as the end point, estimated 5-year survival was 95% (95% confidence interval [CI], 74%-99%), 10-year survival was 68% (95% CI, 45%-86%), and 15-year survival was 53% (95% CI, 31%-74%) (Fig. 1 and Supplementary Table II).

Supplementary Table III and Figure 2 display life tables and Kaplan-Meier curves comparing linked and unlinked groups. Survival of the unlinked group was 93% (95% CI, 64%-100%) at 5 years and 70% (95% CI, 40%-89%) at 10 years. No significant difference was observed in comparing these values to the linked group (5-year survival, 100%; 10-year survival, 69% [95% CI, 28%-94%]).

The earliest implant revision procedure was performed at 2.1 years for painful instability without radiographic signs of loosening occurring in an unlinked prosthesis. The straight ulna component engaged the small curved medullary canal, resulting in tilting of the component (Fig. 3, A and B). In retrospect, this patient would have benefited from preoperative customization of the ulna component. Unfortunately, re-revision of the same component was also required after 7.5 years for aseptic loosening, which caused a breach of the ulna cortex. The elbow continues to function well after second revision in which a cortical strut allograft was used to bridge the defect (Fig. 3, C and D). The same patient also required ulna component revision of the contralateral elbow at 8.17 years for ulna component aseptic loosening and tilting. Four other unlinked prostheses have required

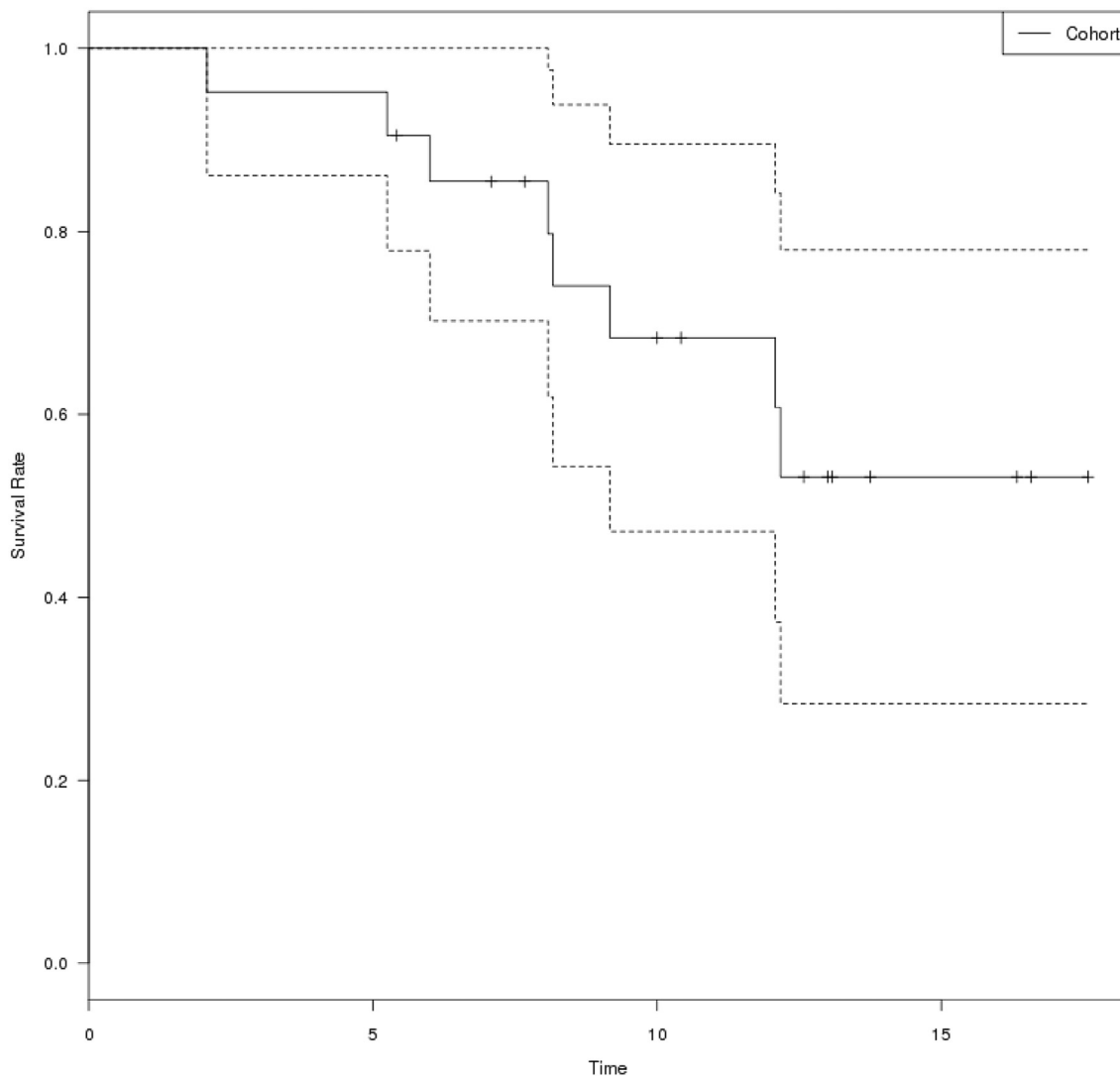


Figure 1 Kaplan-Meier curve for the whole cohort demonstrating survival ratio of total elbow replacement with revision as the end point against time in years. Upper and lower limit 95% confidence interval curves are represented by the *dotted lines*. Censored patients (end of follow-up) are represented by the *marked points*.

revision, all because of painful aseptic loosening of the ulna component. The earliest of these had the ulna component only revised at 8.08 years. At 5 years subsequently, the patient sustained a humeral shaft fracture at the tip of the prosthesis that was successfully managed nonsurgically. However, a refracture occurred after the patient underwent revision of a knee replacement, which necessitated the use of crutches in the postoperative period. This patient is currently awaiting further revision surgery. Another patient had the ulna component revised at 9.17 years because of painful loosening that had resulted in implant erosion and fracture of the proximal ulna. Despite initially doing well, 2 years after revision with an extra-long component and cortical strut allograft, a sinus developed over the olecranon, and the patient has required excision arthroplasty. A third patient with ulna component loosening (12.17 years) was revised to a Coonrad-Morrey prosthesis at another center and con-

tinues to function well. The final unlinked ulna component failure was revised at 12.08 years. At the time of revision surgery, it was found that the surrounding bone and soft tissues could not support an unlinked prosthesis, and hence both components were revised to a semiconstrained Coonrad-Morrey prosthesis. At 12-month follow-up, the patient has good function.

Two linked prostheses were revised in the same patient for painful ulna component aseptic loosening. The first side was revised at 5.25 years but unfortunately became infected and required excision arthroplasty. Both components of the contralateral side were revised at 6.0 years at another center, but this was complicated by further infection and was also salvaged by excision arthroplasty.

Patients who had disease involving both elbows severe enough to warrant bilateral TER were at significantly higher risk of undergoing a revision procedure on either elbow

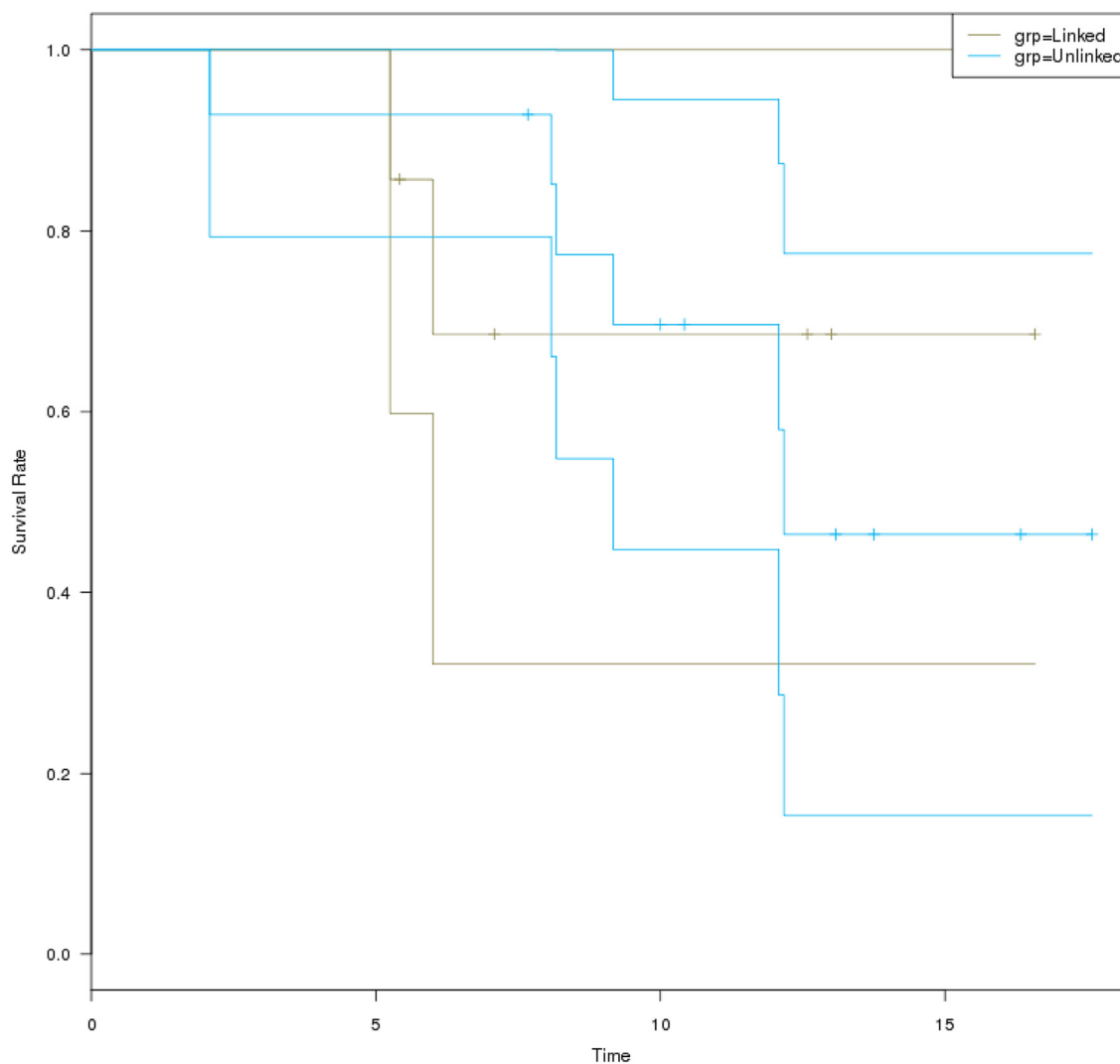


Figure 2 Kaplan-Meier curves for unlinked and linked prostheses demonstrating best case scenario survival of total elbow replacement with revision as the end point against time in years. Upper and lower limit 95% confidence interval curves are represented by the *unmarked lines*. Censored patients (end of follow-up) are represented by the *marked points*.

within 10 years of primary surgery compared with patients who required only unilateral replacement (6/11 vs. 0/7 elbows; $P = .037$; surviving elbows that did not reach year 10 of follow-up were excluded). However, we found no significant difference of the revision rate between those elbows that had surgical intervention before TER and those that had not (4/9 vs. 4/12; $P = .673$).

Pain

Preoperatively, 8 elbows were moderately painful and 13 severely painful (9/14 unlinked, 4/7 linked). At 2-year follow-up, a total of 15 elbows were pain free and 6 mildly painful (4/14 unlinked, 2/7 linked). Excluding revised cases, at latest follow-up 6 elbows were pain free (4/8 unlinked, 2/5 linked), 6 were mildly painful (3/8 unlinked, 3/5 linked), and 1 was severely painful (unlinked) as the patient had sustained a

postoperative traumatic periprosthetic fracture of the humerus but declined intervention at the time of review for this article.

Movement

Overall mean range of motion arc improved from 85° preoperatively to 108° at 2 years postoperatively, and no difference was seen between linked and unlinked groups. Greatest improvement was seen in flexion (preoperative mean range of movement, 32° - 117° ; postoperative, 31° - 139°).

Function

At 2-year follow-up, 20 of 21 elbows had good or excellent function, the other having fair function. Overall, the mean MEPS significantly improved from 26.7 (5-50) preoperatively to 85.0 (65-100) 2 years postoperatively ($P < .000001$).

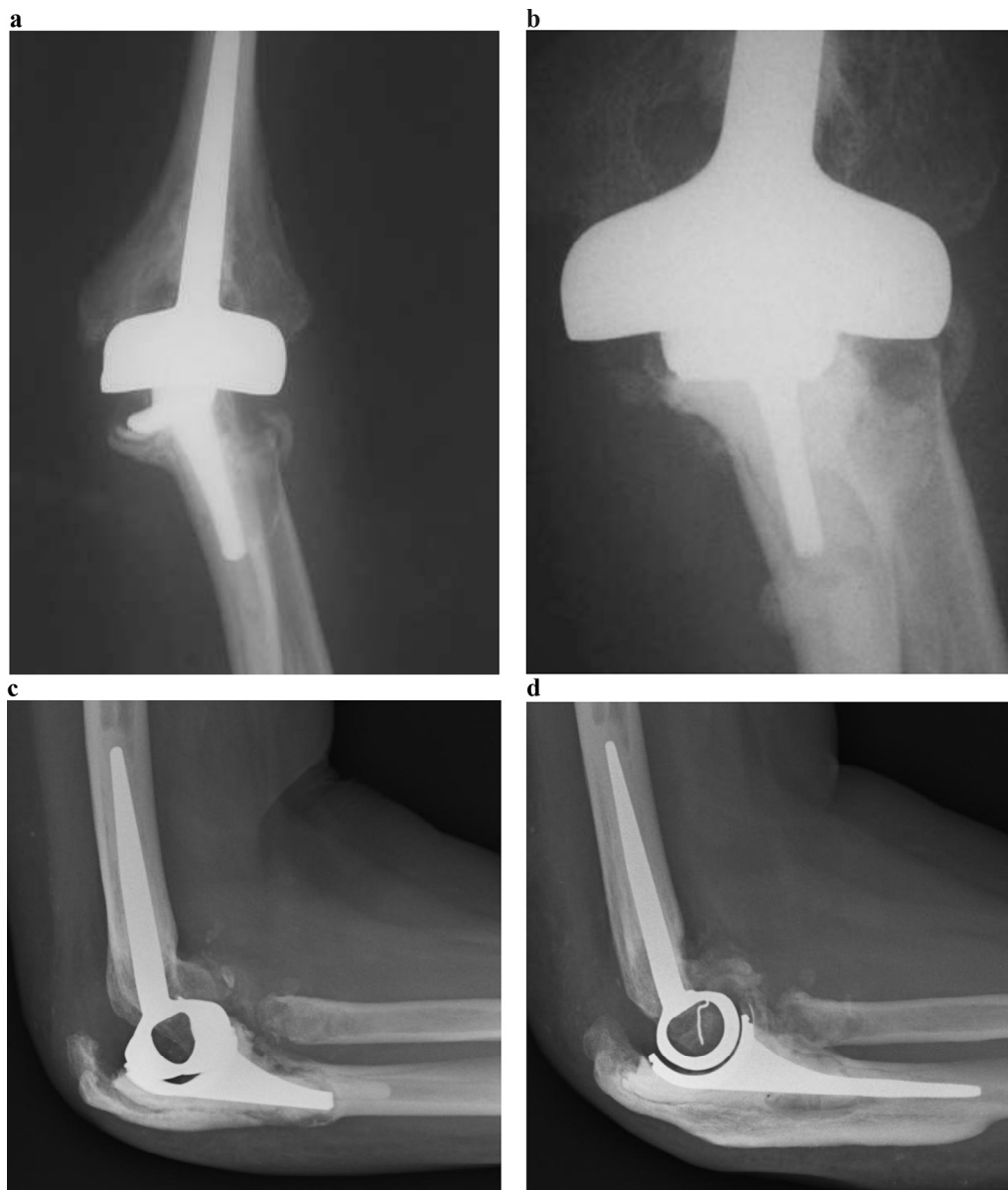

Figure 3 Tilting Kudo ulna component (A) revised to a customized ulna short stem (B) that is no longer deflected radially by the convexity of the intramedullary canal of the proximal ulna. Unfortunately, aseptic loosening and posterior erosion of the ulna occurred subsequently (C), necessitating second revision of the ulna component to a long-stem prosthesis with cortical allograft strut (D).

Excluding the 1 patient mentioned earlier who sustained an untreated periprosthetic fracture of the humerus, the mean MEPS value at latest follow-up was 87.1 (range, 70-100) for the 13 patients who did not require revision. Comparing unlinked and linked groups, the linked group had slightly higher mean preoperative MEPS (31.4 vs. 24.3), but this was not statistically significant ($P = .247$). Functional scores between the groups at 2 years (85.4 vs. 84.3) and latest follow-up (86.4 vs. 88.0) were similar.

Complications

Of 21 elbows, 8 (38.1%) required at least 1 secondary surgical procedure; 6 of these secondary procedures occurred

in the 14 unlinked TERs, and 2 occurred in the 7 linked prostheses.

Of 21 TERs, 7 (33.3%) had early complications (first 2 postoperative years); 4 of 14 in the unlinked group suffered an early complication. There were 4 episodes of ulnar neuritis, of which 3 resolved within 6 months; only 1 patient, who required exploration and neurolysis at 9 months, also had significant stiffness of the elbow requiring arthrolysis.

The early complication profile was different in the linked group; olecranon fracture occurred in 3 of 7 elbows, 2 intraoperative (Fig. 4) and 1 postoperative insufficiency type in the same patient, all managed without surgery. There were no instances of dislocation or postoperative infection following the primary arthroplasty in either group.

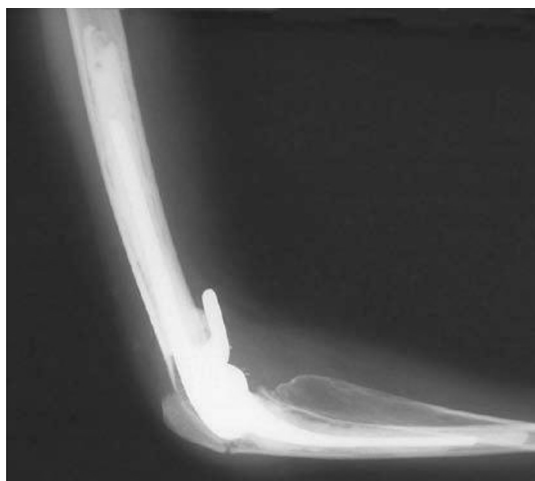


Figure 4 Coonrad-Morrey elbow replacement complicated by intraoperative olecranon fracture.

Radiographs (Supplementary Table IV)

Overall, 15 of 21 elbows showed evidence of loosening on radiography at last follow-up. Of 8 elbows that required revision, 7 showed evidence of radiolucent lines of >1 mm around the ulna component only, and this was combined with ulna component tilting in 1 (unlinked). The other revision was performed for ulna component tilting as previously described. Of 13 surviving prostheses, 7 had evidence of progressive loosening (4 ulna, 2 humerus, 1 both). There was associated ulna component tilting in 1 of these cases (unlinked). However, radiographic follow-up was shorter (mean, 7.5 years) for the 6 surviving prostheses without loosening as 3 of these patients (3 elbows) were not available for radiographic follow-up. Furthermore, 3 of 7 elbows in the linked group (vs. 1 of 14 in the unlinked group) were unavailable for radiographic follow-up beyond 5 years, rendering meaningful direct statistical comparison between the 2 groups impossible. Nevertheless, it is noteworthy that 16 of 19 (84.2%) linked and unlinked prostheses with >5 years of radiographic follow-up (mean, 10.0 years; range, 5.25-16.6 years) had evidence of loosening around at least 1 component. Furthermore, 85.7% of all the unlinked prostheses implanted (12/14) showed evidence of progressive loosening before revision or at latest follow-up.

Discussion

There is a sparsity of published literature describing the outcome of elbow arthroplasty in patients with JIA. Our small series reports the most substantial and contemporary experience of unlinked TER in patients with this condition.

In 1998, Connor and Morrey reported the results of 24 TERs (18 linked Coonrad-Morrey and 6 unlinked capitellocondylar prostheses) in 19 patients with a mean follow-up of 7.4 years.⁵ They did not report a Kaplan-Meier

survivorship analysis, but 2 prostheses were offered early revision for mechanical failure (1 linked and 1 unlinked) within 5 years, and another unlinked prosthesis was revised at 6 years for aseptic loosening. The largest series of linked semiconstrained (Coonrad-Morrey) TER in JIA is that described by Baghdadi et al in 2014 (29 elbows in 24 patients with a mean follow-up of 10.5 years).⁴ They reported an overall 10-year survival rate of 79.9% (95% CI, 65.1%-97.5%); however, this included 1 early revision for infection. Our series was not complicated by infection; hence, a fairer comparison may be with their reported 10-year survival for all other causes (mechanical failure only), which was 82.8% (68.4%-99.8%). Our cohort had a 10-year survival rate of 68% (45%-86%), which appears lower but not significantly so as there is large overlap of CIs. This discrepancy does not appear to be related to the use of an unlinked prosthesis as the 10-year survival estimate for the Kudo prosthesis in this series was slightly higher than for the cohort as a whole. A more likely explanation would be the difference in baseline characteristics of the cohort of patients. There are two indicators that our cohort may have suffered from more severe and earlier onset disease.

First, the number of patients in our cohort requiring bilateral TER was extremely high (7/14 patients) compared with that of Baghdadi et al (5/24 patients) and Connor and Morrey (5/19). We have shown that the 10-year revision rate for these patients is significantly higher than for those who require only unilateral replacement and, to our knowledge, are the first group to make this association. All of our patients have had multiple lower limb arthroplasty procedures including revision surgeries. We recommend that primary lower limb arthroplasty be performed before considering elbow replacement. Revision lower limb surgery is unpredictable and may necessitate prolonged periods of mobilization with walking aids, which in turn places considerable forces through the elbow replacement. Having one elbow replacement means that this can be protected using the other arm, but this becomes impossible with bilateral TERs.

Second, Connor and Morrey reported a mean age at disease onset of 11 years, which is higher than that reported in our cohort (7 years), perhaps reflecting reduced likelihood of skeletal deformity. Baghdadi et al do not report a mean age at onset, but their patients were taken from the same institution during the same period. However, the mean age at surgery is similar to that of our patients (37 vs. 39.5 years, respectively).

The early clinical outcome of TER in our study is remarkably similar to previous series. Postoperative MEPS was 85 (65-100) compared with 86 (60-100) and 90 (55-100) reported in the studies by Baghdadi et al and Connor and Morrey, respectively. Dennis et al also reported a predominant good or excellent outcome on a different scoring scale.⁷ We also found the mean MEPS in our unlinked subgroup to be extremely comparable (85; range, 65-90). Furthermore, mean arc of movement improved by 23° (vs. 27°, 24°, and 25° in

the other series, respectively), with predominant improvement seen in flexion.

Including implant exchange procedures, 38.1% of elbows in our series suffered a complication that required a secondary surgical intervention. This is comparable to the rates reported by Connor and Morrey (41.7%) and Baghdadi et al (28.6%). Connor and Morrey also noted an early complication rate of 37.5%, including 3 superficial infections, 2 condylar stress fractures, 2 episodes of extensor mechanism failure (1 bone, 1 soft tissue), 1 case of joint subluxation (unlinked), and 1 elbow with stiffness requiring manipulation and intensive physical therapy. Although the rate of early complication was similar here (33.3%), the profile was somewhat different, with ulnar neuritis seen in 4 of 14 elbows in the unlinked group and extensor mechanism failure seen in 3 of 7 elbows in the linked group. Ulnar neuritis is a well-described complication after TER and occurs in up to 40% of cases,^{2,9,13} but only 5% are thought to be severe enough to be considered for surgical intervention.¹²

Mean radiographic follow-up in our study was comparable to that reported by Connor and Morrey and Baghdadi et al (8.7 years vs. 6.1 years and 10.3 years, respectively), although Baghdadi et al excluded 6 elbows that had <2 years of radiographic follow-up. We found 15 of 21 (71.4%) primary elbows to have evidence of mechanical failure (14/21 aseptic loosening with >1-mm-thick progressive lucent lines, combined with ulna component tilting in 2 elbows, 1 elbow with tilting only) at latest follow-up. This compares unfavorably with other series (Baghdadi et al, 39%; Connor and Morrey, 16.6%). It is worrying and noteworthy that this may be mostly attributable to the use of the unlinked Kudo 5 prosthesis as the rate of radiographic mechanical failure was 85.7% in this subgroup, although 5 of these 12 patients had good or excellent MEPS and had not required revision at latest clinical follow-up. The difference in baseline characteristics of the cohort, which was mentioned earlier, may also be a contributing factor.

There is continued controversy regarding whether linked or unlinked TER provides the best outcome for patients. Linked implants provide better stability for cases in which there is significant bone loss or stabilizing ligaments are degenerate or sacrificed and therefore have a significant role in JIA elbow disease. For patients who have good bone stock and intact soft tissue stabilizers, the less constrained unlinked implants are theoretically at less risk of mechanical failure.¹⁷ However, this theoretical advantage has not been seen in clinical results. A systematic review by Little et al¹² and Danish registry data of 324 patients¹⁶ found higher incidence of radiographic loosening (especially the Souter-Strathclyde prosthesis) and higher relative risk of revision for unlinked implants, although this is offset by the findings of the Finnish registry that reported no difference in revision rates between designs for 1457 primary TERs performed for rheumatoid arthritis.¹⁸

We used the unlinked Kudo prosthesis as an option for our JIA patients for 2 reasons. First, growth arrest in

JIA results in small skeletal size, meaning that even the smallest off-the-shelf implants may still be too large for this group of patients. The Kudo unlinked prosthesis was manufactured for the morphologically smaller Japanese population, and the standard sizes are more appropriate to our JIA population. Whereas it is generally accepted that the ulna component of the Kudo should be cemented, the results of hybrid fixation are well established in the rheumatoid arthritis population,^{10,19} and we found the use, when possible, of a press-fit humeral component, negating the requirement for cement within the humerus, extremely useful in selected patients. Second, unlinked implants, especially the Kudo prosthesis, generally have shorter stems,¹⁷ which theoretically makes revision easier, although in this population with small and limited bone stock, revision may not be possible at all, and revision has proved to be extremely difficult with a significant complication rate.

There are limitations to our study. It is retrospective with a limited number of patients, especially in the linked group, resulting in wide CIs at 10-year survivorship analysis. Radiographic follow-up was not as complete as clinical data for 3 elbows. Finally, we have not assessed or reported a quality of life score for our patients either preoperatively or postoperatively.

Conclusion

Midterm to long-term improvement in function and pain for patients with symptomatic JIA affecting the elbow joint can be successfully achieved with TER using either the linked Coonrad-Morrey or unlinked Kudo 5 prostheses. There were no cases of dislocation in the unlinked group, but the high rate of radiographic aseptic loosening is a cause for concern, although many of these patients continue to function extremely well without need for revision. There was a high proportion of patients requiring bilateral TER, most of them in the unlinked group, and this was associated with a significantly higher rate of revision at 10 years compared with those who required only unilateral surgery. Complications occurred at a higher rate than for other indications of TER, but few early complications required secondary surgery, and there were no infections after the primary procedure. Revision surgery is difficult and carried a high complication rate, including infection, resulting in salvage by excision arthroplasty in some cases.

Disclaimer

The authors, their immediate families, and any research foundations with which they are affiliated have not received any financial payments or other benefits from any commercial entity related to the subject of this article.

Supplementary data

Supplementary data related to this article can be found online at <http://dx.doi.org/10.1016/j.jse.2016.06.011>

References

1. Adib N, Silman A, Thomson W. Outcome following onset of juvenile idiopathic inflammatory arthritis: I. Frequency of different outcomes. *Rheumatology* 2005;44:995-1001. <http://dx.doi.org/10.1093/rheumatology/keh620>
2. Aldridge JM, Lightdale NR, Mallon WM, Coonrad RW. Total elbow arthroplasty with the Coonrad/Coonrad-Morrey prosthesis: a 10- to 31-year survival analysis. *J Bone Joint Surg Br* 2006;88:509-14. <http://dx.doi.org/10.1302/0301-620X.88B4.17095>
3. Amirfeyz R, Clark D, Quick T, Blewitt N. Newcastle approach to the elbow, a cadaveric study. *Arch Orthop Trauma Surg* 2011;131:747-51. <http://dx.doi.org/10.1007/s00402-010-1206-0>
4. Baghdadi YM, Jacobson JA, Duquin TR, Larson DR, Morrey BF, Sanchez-Sotelo J. The outcome of total elbow arthroplasty in juvenile idiopathic arthritis (juvenile rheumatoid arthritis) patients. *J Shoulder Elbow Surg* 2014;23:1374-80. <http://dx.doi.org/10.1016/j.jse.2014.03.012>
5. Connor PM, Morrey BF. Total elbow arthroplasty in patients who have juvenile rheumatoid arthritis. *J Bone Joint Surg Am* 1998;80:678-88.
6. Dee R. Total replacement of the elbow joint. *Orthop Clin North Am* 1973;4:415-33.
7. Dennis DA, Clayton ML, Ferlic DC, Stringer EA, Bramlett KW. Capitello-condylar total elbow arthroplasty for rheumatoid arthritis. *J Arthroplasty* 1990;5:S83-8.
8. Ewald F, Simmons E, Sullivan J, Thomas W, Scott R, Poss R, et al. Capitellocondylar total elbow replacement in rheumatoid arthritis. Long-term results. *J Bone Joint Surg Am* 1993;75:498-507.
9. Kasten MD, Skinner HB. Total elbow arthroplasty. An 18-year experience. *Clin Orthop Relat Res* 1993;290:177-88.
10. Kudo H, Iwano K, Nishino J. Total elbow arthroplasty with use of a nonconstrained humeral component inserted without cement in patients who have rheumatoid arthritis. *J Bone Joint Surg Am* 1999;81:1268-80.
11. Larsen A, Dale K, Eek M. Radiographic evaluation of rheumatoid arthritis and related conditions by standard reference films. *Acta Radiol Diagn (Stockh)* 1977;18:481-91.
12. Little CP, Graham AJ, Carr AJ. Total elbow arthroplasty: a systematic review of the literature in the English language until the end of 2003. *J Bone Joint Surg Br* 2005;87:437-44. <http://dx.doi.org/10.1302/0301-620X.87B4.15692>
13. Morrey B, Adams R. Semiconstrained arthroplasty for the treatment of rheumatoid arthritis of the elbow. *J Bone Joint Surg Am* 1992;74:479-90.
14. Morrey BF, An K. Functional evaluation of the elbow. In: Morrey BF, Sanchez-Sotelo J, editors. *The elbow and its disorders*. Philadelphia: Elsevier Health Sciences; 2009. p. 80-91. ISBN 1416029028.
15. Packham JC, Hall MA. Long-term follow-up of 246 adults with juvenile idiopathic arthritis: functional outcome. *Rheumatology (Oxford)* 2002;41:1428-35. <http://dx.doi.org/10.1093/rheumatology/41.12.1428>
16. Plaschke HC, Thillemann TM, Brorson S, Olsen BS. Implant survival after total elbow arthroplasty: a retrospective study of 324 procedures performed from 1980 to 2008. *J Shoulder Elbow Surg* 2014;23:829-36. <http://dx.doi.org/10.1016/j.jse.2014.02.001>
17. Sanchez-Sotelo J. Total elbow arthroplasty. *Open Orthop J* 2011;5:115-23. <http://dx.doi.org/10.2174/1874325001105010115>
18. Skyttä ET, Eskelinen A, Paavolainen P, Ikävalko M, Remes V. Total elbow arthroplasty in rheumatoid arthritis: a population-based study from the Finnish Arthroplasty Register. *Acta Orthop* 2009;80:472-7. <http://dx.doi.org/10.3109/17453670903110642>
19. Tanaka N, Sakahashi H, Ishii S, Kudo H. Comparison of two types of ulnar component in type-5 Kudo total elbow arthroplasty in patients with rheumatoid arthritis: a long term follow-up. *J Bone Joint Surg Br* 2006;88:341-4. <http://dx.doi.org/10.1302/0301-620X.88B3.17017>
20. Thomas M. Surgery for juvenile idiopathic arthritis. In: Stanley D, Trail I, editors. *Operative elbow surgery*. London: Churchill Livingstone; 2012. p. 623-36. ISBN 9780702030994.